

Copyright is owned by the Author of the thesis. Permission is given for a copy to be downloaded by an individual for the purpose of research and private study only. The thesis may not be reproduced elsewhere without the permission of the Author.

NEOSPORA AND ABORTION IN NEW ZEALAND DAIRY CATTLE.

A thesis presented in partial fulfilment of the requirements
for the degree of Master Philosophy in Veterinary Science at
Massey University.

Angel Nazareno Patitucci
1994

ABSTRACT.

Neospora caninum is a newly recognized *Toxoplasma*-like protozoan organism that infects dogs; *Neospora* also causes spontaneous abortion and neonatal disease in cattle and other animals although it is not clear if the organism concerned is *N. caninum* or another species. The present study aimed to improve the epidemiological knowledge of bovine *Neospora* abortion in New Zealand and describe the pathologic features of *Neospora* sp. infection in cattle and in dogs.

In a retrospective study of preserved material, *N. caninum* was identified for the first time in New Zealand dogs in histologic sections of the CNS of 3/15 animals with a variety of CNS lesions and nervous signs. The diagnosis was confirmed by immunohistochemistry and, in one case, electron microscopy. Two cases of toxoplasmosis were confirmed but neither *N. caninum* or *T. gondii* could be demonstrated in ten cases with granulomatous meningoencephalomyelitis. In neosporosis the histopathological lesions were distributed more widely throughout the CNS and displayed a more marked inflammatory reaction than in toxoplasmosis cases. In an attempt to transmit the disease to dogs, puppies were inoculated with aborted bovine CNS material infected with *Neospora* organisms but this was unsuccessful.

An epidemiological study of *Neospora* abortion in dairy cattle in the North Island revealed that the disease was diagnosed in 15% of abortion material submitted to Batchelar Animal Health Laboratory and Ruakura Animal Health Laboratory in 1992, thus making it the most frequently diagnosed cause of abortion. Descriptive epidemiologic information including age of aborted fetuses, age of aborting cows and seasonal distribution of the disease were obtained through a questionnaire survey of dairy farmers whose herds experienced *Neospora* abortion that year. Information on risk factors was sought but could not be related to *Neospora* infection because of the small scale of the survey. Nevertheless, some useful preliminary data which could be used in future investigations were obtained. An investigation of a herd with a recent history of neosporosis detected

antibodies in cattle of different age groups using an indirect fluorescent antibody (IFA) test. A "cutoff" point of 1:400 was used in sera obtained one month after an abortion "storm". In all age groups on the farm at the time of the abortion there was a prevalence of approximately 29% (56/194) seropositive. However, the weaner heifers which were off the farm at that time, had a prevalence of 3% (1/32) ($p < 0.01$) seropositive. This finding indicated that all cattle on the farm were exposed to a source of infection at the same time and no age-susceptibility was evident. The significance of these results and directions for future research are discussed.

ACKNOWLEDGEMENTS.

The work presented here would not have been possible without the help of many people. I am grateful to Rotary International for providing me with the financial assistance to undertake this course. I would like to express my special gratitude to my wife Maria Jose for her love, support and endurance during our time in New Zealand.

Recognition needs to go to my supervisors Associate-Professors M. R. Alley and W.A.G. Charleston for their valuable advice and criticism, constant patience and continuous encouragement. Thanks also to Professor B.W. Mantkelow for allowing me to undertake this study in the Department of Veterinary Pathology and Public Health.

I would also like to thank Dr R. Thornton and Dr D. Lake for allowing me to use information and material from the Batchelar and Ruakura Animal Health Laboratories in the preparation of this thesis. Thanks must also go to the veterinarians and farmers involved in the epidemiologic study.

Special thanks are due to Dr D. Pfeiffer and Dr D. Hayes for their advice in the design of the experiments and also with the statistical analysis.

Technical assistance was provided by Mrs P. Slack and Mrs P. Davey in the preparation of histological and ultrastructural material as well as Mr M.J. Birtles and Mr R. Sparksman with the immunohistochemistry procedures. I am grateful for their excellent work.

Finally I wish to express my sincere appreciation to all those people who were involved in our stay in New Zealand. I first planned to identify individuals but changed my mind because I may inadvertently overlook someone. Many unforgettable memories both within and outside of Massey University remain with us. Thanks very much to all of you.

TABLE OF CONTENTS.

GENERAL INTRODUCTION	1
CHAPTER 1	4
LITERATURE REVIEW	4
1. Protozoal disease (neosporosis, toxoplasmosis, sarcocystosis) of ruminants.	4
1.1 General morphology and life cycles of the phylum Apicomplexa.	4
1.2. <i>Neospora caninum</i> & <i>Neospora</i> -like organisms.	7
1.2.1 Introduction and history.	7
1.2.2 Structure and life cycle.	9
1.2.2.1 Tachyzoites	9
1.2.2.2 Tissue cysts and bradyzoites.	11
1.2.3 Host range and distribution.	12
1.2.4 Experimental and natural transmission.	13
1.2.5 Isolation and cultivation.	14
1.2.5.1 Cell culture.	14
1.2.5.2 Isolation in laboratory animals.	14
1.2.6. Host-parasite relationship.	15
1.2.7 <i>Neospora</i> -induced abortions in cattle.	16
1.2.7.1 Introduction and history.	16
1.2.7.2 Epidemiology.	17
1.2.7.3 Clinical signs and pathology.	19
1.2.7.4 Diagnosis and control.	21
1.3. <i>Toxoplasma gondii</i> .	23
1.3.1 Structure and life cycle in comparison with <i>N. caninum</i> .	23
1.3.2 Abortion in sheep and goats.	26
1.3.2.1 Sheep.	26
1.3.2.2 Goats.	28
1.3.3 Toxoplasmosis in cattle.	29
1.4. <i>Sarcocystis</i> spp.	30
1.4.1 Structure and life cycle in comparison with <i>N. caninum</i> .	30
1.4.2 Sarcocystosis in cattle.	32
1.4.3 Sarcocystosis in sheep.	34
1.4.4 Sarcocystosis in goats.	35

CHAPTER 2	36
2. EXAMINATION OF TISSUE INFECTED WITH <i>NEOSPORA</i> SPP.	36
2.1. Dogs.	36
2.1.1 Introduction.	36
2.1.2 Materials and methods.	37
2.1.3 Results.	38
2.1.4 Discussion.	50
2.2. Cattle.	54
2.2.1 Introduction.	54
2.2.2 Materials and methods.	55
2.2.3 Results.	56
2.2.4 Discussion.	59
2.3. Attempted transmission of <i>Neospora</i> spp. to dogs.	61
2.3.1 Introduction.	61
2.3.2 Materials and methods.	61
2.3.3 Results.	63
2.3.4 Discussion.	63
CHAPTER 3.	65
3. A SEROLOGICAL STUDY OF A <i>NEOSPORA CANINUM</i> INFECTED DAIRY HERD.	65
3.1 Introduction.	65
3.2 Materials and methods.	67
3 Results.	69
3.4 Discussion.	72
CHAPTER 4.	77
4. AN EPIDEMIOLOGICAL STUDY ABORTION DUE TO <i>NEOSPORA</i> SP. IN DAIRY HERDS IN THE NORTH ISLAND.	77
4.1 Introduction.	77
4.2 Materials and methods.	77
4.3 Results.	80
4.4 Discussion.	85

5.	CHAPTER 5.	89
	SUMMARY AND CONCLUSIONS.	89
	APPENDIX: Survey forms.	92
	REFERENCES.	96

LIST OF FIGURES.

		Page
Figure 2.1	Section of spinal cord from dog (N° 11383) infected with <i>N. caninum</i> . There is severe myelitis and protozoan organisms (arrows) are scattered throughout the neuropil. H&E x65	41
Figure 2.2	<i>Neospora caninum</i> cysts in the spinal cord of a dog (N° 11383) without any associated inflammatory reaction. Note the thick capsule. H&E x650	41
Figure 2.3	Ultrastructure of a tissue cyst (10.9x6.3µm) of <i>N. caninum</i> in the brain of case N° 11383. Note the thick (0.6µm) granular, cyst wall (0.6µm) (w) and bradyzoites (b). TEM x7,800	43
Figure 2.4	Ultrastructure of part of a large tissue cyst (26x16µm) of <i>N. caninum</i> in the brain of a dog (N° 11383). The cyst wall (w) is 1.7µm thick and the cyst contain numerous bradyzoites (b). TEM x5,200	43
Figure 2.5	Higher magnification of part of the cyst shown in Fig. 2.4. Nuclei (n), micronemes (m), electron dense bodies (d) and amylopectin granules (a). TEM x11,200	44
Figure 2.6	Anterior end of a <i>N. caninum</i> bradyzoite, with conoid (c), many micronemes (m), rhoptries (r) and an electron dense body (d). TEM x48,600	44
Figure 2.7	Group of zoites of <i>N. caninum</i> (arrow) and individual zoites (arrow head) in a dog. ABTC x680	45
Figure 2.8	<i>N. caninum</i> cyst-like structure in dog brain. ABPC x680	45
Figure 2.9	Section of the brain from dog N° 6519 infected with <i>Toxoplasma gondii</i> . Note the mild inflammatory reaction associated with the parasites. H&E x65	47
Figure 2.10	Dog brain infected with <i>T. gondii</i> showing typical cyst. ABPC x650	49
Figure 2.11	A focus of non-suppurative inflammatory necrosis in the brain of an aborted bovine foetus. H&E x65	57
Figure 2.12	A focus of necrosis and desquamation of the trophoblast epithelium in an aborted bovine placenta infected with <i>Neospora</i> . Moderate numbers of mononuclear cells are present in the chorioallantoic membrane. H&E x68	57

Figure 2.13	Necrosis and desquamation of the trophoblast epithelium. H&E x350	58
Figure 2.14	The brain of an aborted bovine foetus showing individual zoites of <i>Neospora</i> (arrows) within an inflammatory focus. ABPC x680	58
Figure 3.15	Histogram: Percentage of cattle positive to the <i>Neospora</i> IFA test of different age groups.	70
Figure 3.16	Tachyzoites of <i>Neospora</i> in a positive indirect fluorescent antibody test. Note the brightness of the whole parasite. x400	71
Figure 3.17	Tachyzoites of <i>Neospora</i> in a negative sample of indirect fluorescent antibody test. Note the apical brightness at the anterior end of the parasite. x800	71
Figure 4.18	Histogram: Abortions per month on <i>Neospora</i> infected farms vs. non-infected farms.	82
Figure 4.19	Histogram: Mean age of aborted foetuses from <i>Neospora</i> infected farms.	83

GENERAL INTRODUCTION.

In most cattle raising countries, bovine foetal death and abortion are important causes of economic loss. The severity of the problem varies for each nation and also between regions of the same country, often depending on the presence or absence of abortifacient entities such as brucellosis.

In a large percentage of these abortions however, the cause remains obscure. Ordinarily the diagnostic rate varies between 20 to 25% of cases examined (Hubbert *et al.* 1973; Kirkbridge 1985a) approaching a maximum of 40% in well-equipped laboratories with well-trained staff working with high quality submitted material. Therefore, in most countries more than half of bovine abortions remain undiagnosed. Diverse reasons have been given to explain this low success rate (Elder *et al.* 1985; Thurmond *et al.* 1990) but most research workers agree that more detailed investigations are needed to solve the problem.

Infectious diseases are commonly believed to be responsible for a large proportion of bovine abortions (Barr & Anderson 1993). The numerous agents which can cause abortion have been listed by Kirkbride *et al.* (1973) and Barr & Anderson (1993) but what causes some diseases to have a higher prevalence in some regions than in others is poorly documented and poorly understood. There is no doubt that the host-environment-agent triad influences these diseases making them complex and dynamic. In recent surveys conducted in the USA (Anderson *et al.* 1991), Britain (Trees *et al.* 1993), New Zealand (Thornton *et al.* 1992) and Australia (Munday *et al.* 1990) fetuses with lesions suggestive of protozoal infection comprised the largest category of diagnosed aetiologies of bovine abortion. In the majority of these cases the diagnosis was tentative only because the parasite could not be identified beyond it being a protozoan organism resembling *Neospora* spp. or *Sarcocystis* spp. There is now mounting evidence that protozoal abortion has a worldwide distribution and its presence is recognised in many countries

(Anderson *et al.* 1991, 1992; Barr *et al.* 1992).

Estimates of the monetary value of bovine abortion are scarce and exact figures are difficult to calculate because of the many factors involved (Olds *et al.* 1979). Under New Zealand farming conditions where milk production is mostly seasonal with a common "drying off" date, the main loss will be determined by what happens to the cows which abort. If the aborted cow is culled after completing her lactation the main cost would involve her replacement (replacement cost = in-calf heifer cost - culled cow value). An approximate current estimate would be \$500/aborted cow. If the cow is kept and reinseminated the main cost would be the days without production and the cost of feeding (\$7-10 of feed/week, Holmes pers. comm.). This again results in a value of \$500/per aborted cow. Although national figures for abortion in New Zealand are not available, it has been estimated that on farms affected by neosporosis an average of about 6% of cows may abort (Thornton *et al.* 1991). Thus an average affected dairy farm in New Zealand with a herd of 180 cows (Holmes pers. comm.) could lose \$5500 annually (11 cows x \$500). The estimated \$500/per abortion does not take into account the calf loss, reinsemination cost, etc. and is therefore an underestimate.

Welfare considerations related to the abortion should not be neglected and in herds with high abortion rates there is no doubt that the animals suffer stress. Moreover, since there is no treatment for the majority of them and by the time the abortion is noticed it is too late to implement treatment, farmers may feel helpless. For this reason, more emphasis should be placed on prevention but this can only be achieved through a better understanding of the aetiology, epidemiology and pathology of the diseases responsible.

Taking into consideration the magnitude of the losses caused by the abortion, the low current diagnostic success rate as well as the welfare aspects of the disease, it can be seen that research work into bovine abortion has great potential for

improving animal health. The emergence of protozoal disease as an important contribution to the problem in New Zealand has prompted the present investigation.

CHAPTER 1.

LITERATURE REVIEW.

1. Protozoal disease (neosporosis, sarcocystosis, toxoplasmosis) of ruminants.

Protozoa can be found in all habitats, from tropical rain forests and oceans to Arctic snows. Among their habitats are the organs and tissues of other living animals and in some of them they may cause disease.

The protozoa form a sub-kingdom of the kingdom Protista. In the latest classification (Levine et al. 1980), the Society of Protozoologists recognized seven phyla. Three of these phyla; the Sarcomastigophora, Ciliophora and Apicomplexa are larger than the others and are considered to be relatively more important. Of these groups, the apicomplexans are by far the most important as disease causing agents in domesticated animals. This review will be chiefly concerned with those apicomplexans which have been shown to cause abortion in ruminants.

1.1 General morphology and life cycles of the phylum Apicomplexa.

The distinctive feature of this phylum is the characteristic apical complex present at the anterior end of the organism at some stage of its life. The complex consists of a number of structures, some of which have been lost by some groups.

Ultrastructural studies (Sheffield and Melton 1968; Bjerkås and Landsverk 1986; Nichols and Chiappino 1987) have shown that the outer structure of these protozoa consists of one or more electron dense **polar rings**, inside of which is the **conoid**, a hollow truncated cone composed of a number of spirally coiled microtubules. Passing through the conoid are the necks of a number of **rhoptries** (from the Greek word for club), electron-dense long-necked sacs of uncertain function which may perhaps secrete enzymes used in cell penetration. Alongside the rhoptries

in the cytoplasm are a large number of short rod-like **micronemes**, which some workers believe are attached to the rhoptries, and running backward from one of the polar rings are **subpellicular microtubules**, whose number varies with the group and which are probably concerned with both locomotion and support. In addition, there are one or more **micropores** which are apparently used for nutrient intake.

Most of the important Apicomplexa fall into five main groups. Perhaps the most primitive of these are the **gregarines** which are parasites of invertebrates (Watson 1916). They were originally described in the 19th century. There is now renewed interest in this group because of their potential use for biological control of some disease vectors (Manwell 1977).

A second group is composed of the **hemogregarines** which, despite their name, are not a subgroup of the gregarines. They live in the blood cells of fish, reptiles, and other vertebrates (Manwell 1977). In fact, relatively little is known about the hemogregarines. Few appear to be pathogenic, and since they occur mostly in lower vertebrates, there has been little incentive to study them (Levine 1988).

The third group of Apicomplexa are the **coccidia** (Ruff & Reid 1977, Todd & Ernst 1977). These are important parasites of domestic animals and man. Coccidia occur in all vertebrates which have been examined for them to date and also in a few invertebrates. Chickens, turkeys, and other birds, cattle, sheep, goats, pigs, dogs, cats, rabbits, rats, and mice are especially affected. Each host is usually infected by several species of coccidia the great majority of which are host specific. They most commonly multiply inside intestinal cells, and produce heavy-walled cysts (oocysts) which are shed in the faeces. After a variable period shed oocysts become infective.

Electron microscope studies and more lately, transmission experiments, revealed that *Toxoplasma gondii*, *Sarcocystis* spp.,

and related genera are also coccidia but with less usual life cycles (Dubey 1977). They are heteroxenous, with a predator-prey life cycle in which the asexual stages occur in a prey animal and the sexual stages in the predator.

A fourth group, the **hemosporida**, is composed of blood parasites, including the malarial parasites. They multiply in erythrocytes and are transmitted by mosquitoes or other biting flies. Malaria occurs in man, monkeys, rodents, many birds, and reptiles. It is still the most important protozoal disease of man attacking about 150 million people a year and killing about 1.5 million. More has been written about malaria parasites than about any other protozoa, although their life cycles were unknown until the turn of the century (Levine 1988).

The fifth group of Apicomplexa, the **piroplasms**, is as important in livestock as the malaria parasites are in man. They too multiply in erythrocytes and in some cases, other cells, but are transmitted by ticks rather than by mosquitoes or biting flies. Piroplasms cause serious diseases of cattle in India, Africa, North, South and Central America, Australia, Europe and the former U.S.S.R. (Levine 1988).

The basic pattern of apicomplexan reproduction is alternation of sexual and asexual phases. A zygote is formed by fusion of gametes (syngamy). It divides by multiple fission (sporogony) to form sporozoites (so-called because they were all traditionally thought to be formed within spores; actually, some are and some are not). Sporozoites are infective trophozoites. They enter host cells, grow and become meronts. These divide asexually by multiple fission, endodyogeny or endopolygeny, a process known as merogony, to produce a number of merozoites (from the Greek mero = parts). There may be one or more generations of meronts and merozoites. If there is more than one, the merozoites enter new host cells, become meronts, and produce more merozoites. Finally, some merozoites become macrogamonts or macrogametes, while others become microgamonts. The microgamonts,

if formed, divide by binary or multiple fission to form two or more microgametes. A microgamete fuses with a macrogamete to form a zygote. These produce sporozoites, and the cycle is repeated.

There are thus three multiplication phases in the basic apicomplexan life cycle. These are merogony, gamogony, and sporogony. This basic life cycle is modified in different groups.

1.2 *Neospora caninum* / *Neospora*-like organisms.

1.2.1 Introduction and history.

In 1984, Bjerkås *et al.* reported a *Toxoplasma*-like disease in seven Norwegian dogs. The affected animals were born to a single dam and came from three successive litters. Six of the dogs suffered ataxia and paresis at the age of 2 - 5 months. Histopathological studies revealed that these animals had encephalomyelitis and myositis resembling that associated with *T. gondii* infection. However, none of the dogs had antibodies against *T. gondii*.

Four years later, Dubey *et al.* (1988a) in a retrospective study, found a similar parasite in 10 of 23 dogs with a previous diagnosis of fatal *Toxoplasma*-like illness at the Angel Memorial Animal Hospital in the U.S.A. He identified the new parasite as a cyst-forming apicomplexan and named it *N. caninum* (Dubey *et al.* 1988a). Further study of the Norwegian dogs by Bjerkås and Dubey (1991) revealed that they were affected with an identical or closely related parasite to that seen in the U.S.A.

Fatal *Toxoplasma* infection in dogs was first recognised in Turin, Italy by Mello in 1910. Since that time, many cases have been reported from different countries (Dubey & Beattie 1988). Most of these cases were identified by histological examination and rarely was the diagnosis confirmed by isolation of *T. gondii* or by immunologic techniques. It is now suspected that the death

of some of these dogs may have been caused by *N. caninum* infection.

Despite its relatively short history the disease is not new. Cases of fatal canine neosporosis were found in histologic sections of material processed in the U.S.A. 1957 - 1958 (Dubey *et al.* 1988a; Dubey 1990a).

Neosporosis in cattle was recognised after the discovery of *Neospora caninum* in dogs (Dubey *et al.* 1988a) and since then the parasite has been described as having a close morphological resemblance to *T. gondii*; the reason for misdiagnosis of the disease on the past. After the parasite was named (Dubey *et al.* 1988a), it was placed in the phylum of Apicomplexa as a new genus in the family of Sarcocystidae, together with the genera *Toxoplasma*, *Sarcocystis*, *Hammondia*, *Besnoitia* and *Frenkelia*, but taxonomists have always had problems with the correct identification of these parasites. Thus *Sarcocystis* sp., *Besnoitia* sp. and *Frenkelia* sp. are differentiated from one another by the morphology of the cyst wall and/or the number of bradyzoites within the tissue cyst (Speer & Dubey 1989; Barr *et al.* 1991). However, *T. gondii* and *Hammondia hammondi* are structurally identical to each other (Sheffield 1968; Mehlhorn & Frenkel 1980; Speer & Dubey 1989). *Neospora caninum* cysts are known to have thicker walls than the maximum reported for *T. gondii* and *H. hammondi* (Barr *et al.* 1992) and tachyzoites of *N. caninum* show slight differences in organelles such as rhoptries which provide a method for distinguishing between these two parasites (Dubey 1992a; Dubey & Lindsay 1993). Antigenic differences have been also used in the identification (Lindsay & Dubey 1989a). Despite these differences however, recent studies based on DNA sequence analysis (PCR) and immunological studies concluded that *T. gondii* and *N. caninum* should be placed in the same genus (Holmdahl *et al.* 1994; Ellis *et al.* 1994; Barta and Dubey 1992).

The development of specific antiserum to *N. caninum* (Lindsay and Dubey 1989a) has made possible the diagnosis of *Neospora* infection in other animals (Dubey 1992a) and *Neospora*-like organisms are now recognised as a common cause of abortion in cattle and are associated with extensive losses to the livestock industry (Thilsted and Dubey 1989). Although the organism isolated from cattle closely resembles *N. caninum* (Conrad et al. 1992), whether these two parasites are identical species or not remains uncertain at the time of writing.

1.2.2 Structure and life cycle.

The life cycle of *N. caninum* is not known but since most cyst-forming coccidia are facultative or obligatory 2-host parasites, it is likely that a predator (carnivore) may serve as the definitive host. However, the host in which sexual reproduction and formation of oocysts takes place is currently the unknown link in the life cycle of this parasite. Tachyzoites and tissue cysts are the only stages which have been characterized to date.

1.2.2.1 Tachyzoites

When sectioned longitudinally, tachyzoites appear crescentic or nearly fusiform in shape, measuring approx. 3-7 x 1-5 μm . They change in shape to ovoid or globular when dividing. Mother *Neospora* tachyzoites divide into two daughter cells by endodyogeny as does *T. gondii* (Sheffield and Melton 1968). One divisional cycle requires less than 12 hours (Lindsay & Dubey 1989b).

The parasitic tachyzoites are not cell-specific and can be found in neural cells (neurons, ependymal cells, Schwann cells, retinal cells, astrocytes), macrophages, fibroblasts, vascular endothelial cells, myocytes, renal tubular epithelial cells, hepatocytes and many other cells of the body (Cummings et al. 1988; Dubey et al. 1988a; Bjerckås & Presthus, 1989; Dubey &

Lindsay, 1989b; Speer & Dubey, 1989). Within the host cell the tachyzoites can be found free in the cytoplasm or inside a parasitophorous vacuole (PV). When they are within a PV, structures such as stereocilial or microvillus projections, similar to those consistently seen in *T. gondii* infection (Jones *et al.*, 1972; Sheffield & Nelson 1968), may be present (ranging from a few to many) or absent (Cummings *et al.* 1988; Dubey & Beattie 1988; Dubey *et al.* 1988a).

The tachyzoites contain ultrastructural features that are characteristic of other closely related cyst-forming coccidia. The tapered anterior end has the characteristic apical complex. Organelles include 1-3 mitochondria, ribosomes, lipid bodies, electron dense bodies, a Golgi complex, rough and smooth endoplasmic reticulum, a nucleus and a nucleolus (Speer & Dubey 1989; Cummings *et al.* 1988; Bjerkås & Presthus 1988).

On the other hand, *Neospora* tachyzoites also have some unusual and controversial ultrastructural characteristics, namely:

i) Eight to eighteen electron dense rhoptries, located anterior to the tachyzoite nucleus (Bejerkas *et al.* 1984; Dubey 1992a). There is some discrepancy in the number of rhoptries reported by different researchers which may be due to the difficulty in distinguishing rhoptries from dense granules (Dubey & Lindsay 1993). Some tachyzoites can present posteriorly located rhoptries (Lindsay *et al.* 1993a).

ii) Micropores are absent in tachyzoites obtained from infected animals. However, they can be observed in tachyzoites grown in cell culture (Speer & Dubey, 1989, Lindsay *et al.* 1993a).

iii) Many anterior micronemes which are described as perpendicular to the inner parasite membrane by some authors working with organisms from naturally-infected dogs (Speer and

Dubey 1989; Dubey *et al.* 1988a, Dubey 1992a), or parallel to the pellicular membrane by others working with cell cultures of organisms isolated from dogs (Lindsay *et al.* 1993a) and cattle (Conrad *et al.* 1993). They also have a few micronemes posterior to the parasite nucleus.

The differences in morphology of tachyzoites obtained from these different sources raises the possibility that some of the ultrastructural features of *N. caninum* may be altered by *in vitro* cultivation.

1.2.2.2 Tissue cysts and bradyzoites.

Neospora tissue cysts, which contain the bradyzoites, are rare and only found in neural tissue (brain, spinal cord and retina). They are found in the cytoplasm of neurons or in unidentified cells in the neuropil (Barr *et al.* 1991; Dubey 1992a).

Experimentally, tissue cysts can form as early as 17 days after inoculation (Lindsay & Dubey 1989c) and have been found in animals inoculated up to 13 months previously (Lindsay *et al.* 1992). They are often round or oval, measuring up to 107 μ m in diameter and contain 50-200 bradyzoites. Occasionally 1-2 leaflets of host-cell endoplasmic reticulum adhere to the outer surface of the parasitophorous vacuole (PV) (Speer and Dubey 1989).

The cyst wall lacks septa and normally is 1.5 to 2 μ m thick, although it can be up to 4 μ m depending upon how long the infection has existed (Dubey *et al.* 1988a; Dubey & Lindsay 1993). Histochemically, it is argyrophilic and stains variably with periodic acid-Schiff (PAS). The cyst wall contains tubule-like structures (Bjerkås *et al.* 1984; Barr *et al.* 1991).

The cystic organisms (bradyzoites) are more slender (6 to 8 x 1 to 1.8 μ m), and more densely packed than the tachyzoites.

The organelles of the bradyzoites are basically the same as those of the tachyzoites with fewer rhoptries and more PAS-positive granules.

The presence of micropores in bradyzoites was described by Bjerkås and Presthus (1989), although this feature has not been reported since by other workers. However, the number of tissue cysts examined has been very few, and age of the cyst and fixation procedures used may affect these structures. Better information on the fine structure will be available when a large number of tissue cysts can be produced by experimental transmission (Dubey 1992a).

1.2.3 Host range and distribution.

Natural infections in dogs have been found in Norway (Bjerkås *et al.* 1984; Hilali *et al.* 1986), Sweden (Ugla *et al.* 1989), France (Fritz 1992; Bourdoiseau 1993), U.S.A. (Dubey *et al.* 1988a,b; Cummings *et al.* 1988; Hay *et al.* 1990; Gasser *et al.* 1993), England (Dubey *et al.* 1990a; Trees *et al.* 1993); Belgium (Poncelet *et al.* 1990), Ireland (Sheahan *et al.* 1993); Canada (Cochrane & Dubey 1993), South Africa (Jardine & Dubey 1992; Jacobson & Jordine 1993), and Australia (Munday *et al.* 1990).

A disease in neonatal calves that resembles neosporosis has been reported to occur in the U.S.A. (Dubey *et al.* 1989a, Shivaprased *et al.* 1989); England (O'Toole & Jeffrey 1987; Dubey 1989) and Australia (Dubey *et al.* 1990b).

Neospora or *Neospora*-like parasites have also been found in the brain and spinal cord of a 1-week-old lamb (Dubey *et al.* 1990c), in the lung of an aborted equine fetus (Dubey & Porterfield 1990) and in stillborn and aborted caprine fetuses (Dubey *et al.* 1992a; Barr *et al.* 1992).

1.2.4 Experimental and natural transmission.

The organism can be experimentally transmitted to dogs, cats, mice, rats, gerbils, cattle and sheep (Dubey 1990a; Cuddon *et al.* 1992; Lindsay & Dubey 1989c,d; Dubey *et al.* 1990d; Dubey & Lindsay 1989a,b,c; 1990a).

Tachyzoites are infective experimentally by ingestion or by subcutaneous, intramuscular and intraperitoneal inoculation. *N. caninum* bradyzoites are infective by oral ingestion and subcutaneous inoculation (Lindsay & Dubey 1990).

Bradyzoites are also resistant to acid-pepsin *in vitro* treatment (Lindsay & Dubey 1990) which suggests that carnivores are part of the *N. caninum* life cycle even though oocysts have not been detected in faeces of experimentally infected dogs and cats (Cuddon *et al.* 1992).

Bradyzoites of *N. caninum* within tissue cysts in the brains of experimentally inoculated mice can survive for at least 14 days at 4 C but are killed by freezing at -20 C for 1 day (Lindsay *et al.* 1992).

Transplacental infection is the only known natural route of infection (Bjerkås & Presthus 1988; Dubey 1990a). It has been experimentally induced in cats (Dubey & Lindsay 1989a), dogs (Dubey & Lindsay 1989c), sheep (Dubey & Lindsay 1990a), mice (Cole *et al.* 1991 cited by Dubey 1992a) and cattle (Dubey *et al.* 1992b). Repeated transplacental infection has also been recorded in dogs (Bjerkås & Presthus 1988; Dubey *et al.* 1988b) and in cats, *N. caninum* can be transmitted transplacentally both when the infection was acquired during pregnancy and in infection acquired before pregnancy (Dubey & Lindsay 1989a).

1.2.5 Isolation and Cultivation.

1.2.5.1 Cell culture.

The cell cultures from which the organism was first isolated were bovine monocytes (B.M.) and bovine cardio-pulmonary arterial (C.P.A.) endothelial cells (Lindsay & Dubey 1989b; Dubey *et al.* 1988b). However, several other well-established cell lines are also suitable for cultivation of *N. caninum* (Cole *et al.* 1992 cited by Dubey 1992a).

Tachyzoites are the only parasitic stage seen in cultivated cells. In several studies, the zoites were seen multiplying by endodyogeny, apparently by the same process as described for *T. gondii* (Sheffield & Melton 1968; Dubey *et al.* 1988a; Speer & Dubey 1989; Lindsay *et al.* 1993a). In flasks of cell culture inoculated with infected tissues from dogs, tachyzoites of *N. caninum* in the endodyogenic stage can be seen after 1 day postinoculation (PI) (Lindsay & Dubey 1989b).

Cytopathogenic effects consisting of "hole" formation in the monolayer and rupture of infected host cells were first seen 3 days after inoculation (Lindsay & Dubey 1989b).

Tachyzoites obtained from cell cultures have been used successfully to infect dogs (Dubey *et al.* 1988b; Lindsay & Dubey 1990b).

1.2.5.2 Isolation in laboratory animals.

Mice (*Mus musculus*) (Dubey *et al.* 1988b; Lindsay & Dubey 1989c; 1990a,b), and rats (*Rattus norvegicus*) (Lindsay & Dubey 1989c) are the laboratory animals which have been used for the isolation of *N. caninum*.

Normal immunocompetent mice and rats seem to be resistant to infection with viable *N. caninum* tachyzoites. However, disease

can be produced by treating the animals with methylprednisolone acetate (MPA). Variation of expression of the disease (subacute or chronic) may be produced by manipulating the dosage of MPA and the number of tachyzoites inoculated (Lindsay & Dubey 1989d). Furthermore, different strains of mice differ in their susceptibility to infection and *N. caninum* can cause lethal infection in certain strains of inbred mice not given corticosteroids (Dubey 1992a).

Although lesions were present in most of the organs in both mice and rats, encephalitis and pneumonia were the main lesions in the mice (Lindsay & Dubey 1989d; 1990a; 1990b), whereas hepatic necrosis was the most striking finding in rats (Lindsay & Dubey 1989c).

1.2.6 Host-parasite relationship.

Abundant evidence now indicates that *N. caninum* does not affect all animals with the same severity, and infection is not always fatal (Dubey *et al.* 1988b, Dubey 1990a).

N. caninum is considered a primary pathogen of dogs and probably in some other animals and no other concurrent undermining disease has been reported (Dubey *et al.* 1988a; Dubey 1993). However, immunosuppression caused by administration of corticosteroids can exacerbate acute or chronic neosporosis in experimentally infected animals. Neither breed predisposition nor sex susceptibility has been described in dogs or other animals (Dubey 1990a).

The mechanism of pathogenesis of *N. caninum* is not yet fully understood. Since the foetus can be affected from a chronically infected dam, parasitaemia must be a feature of the disease. It is known that it is an intracellular parasite that can rapidly kill host cells by active multiplication of tachyzoites. However, whether or not toxic products are liberated by *N. caninum* has not been determined (Dubey 1990a). The organism can destroy a variety

of neural cells producing a severe neuromuscular disease in dogs and probably other animals. The presence of tachyzoites in the brain and spinal cord is associated with foci of gliosis with or without central necrosis, and perivascular mononuclear cuffing (Dubey & Lindsay 1990b; Dubey et al 1988a,b).

Tissue cysts scattered throughout the CNS are often not surrounded by a zone of host reaction. However, with degenerate cysts or free bradyzoites, a granulomatous inflammatory response is commonly developed by the host (Dubey 1990a; Dubey et al. 1990c; 1992a).

1.2.7 Neospora-induced protozoal abortion in cattle.

1.2.7.1 Introduction and history.

In the last decade, aborted bovine fetuses with a distinct pattern of inflammatory lesions have been seen in veterinary diagnostic laboratories throughout New Zealand (Johnstone, personal communication) and overseas (Barr et al 1990; Anderson et al. 1990). The lesions consisted of focal non-suppurative necrotizing encephalitis and myocarditis and resembled those seen in *T. gondii* infections of sheep (Hartley & Kater 1963; Dubey & Beattie 1988). Since cattle appear to be resistant to *T. gondii* infections (Dubey 1986), investigations were begun into the cause of these abortions.

In 1988, a *Neospora*-like parasite was first identified in two aborted fetuses from a Holstein dairy herd in New Mexico, USA (Thilsted & Dubey 1989). Later, similar parasites were found in a stillborn beef calf born from a Shorthorn heifer in Maryland, USA (Dubey et al. 1990e). Retrospective studies found similar protozoal infections in other states of the USA (Parish et al 1987, Dubey et al. 1989a, Shivaprasad et al. 1989) and in Australia (Dubey et al. 1990b). The organism has been now implicated as a major cause of abortion in dairy cattle in California (Barr et al. 1990; 1991; Anderson et al. 1990; 1991;),

New Zealand (Thornton *et al.* 1991) and Great Britain (Otter *et al.* 1993).

It has still not been determined if dogs and cattle are affected by the same parasite or different strains of the same species. The literature on this topic is somewhat confused and the use of the terms *N. caninum*, *N. caninum*-like, *Neospora* sp., *Neospora*-like for the parasite found in herbivores adds to the problem. The parasites examined to date seem to be structurally similar, although some differences have been noticed between *in vivo* and *in vitro* studies (Conrad *et al.* 1993a). However, immunologic studies tend to suggest that there are different strains of *Neospora* spp. (Barr *et al.* 1991; Conrad *et al.* 1993a). The *Neospora* strain derived from cattle is similar to the dog strain and reacts strongly against anti-*N. caninum* sera. The bovine strain, in contrast with the dog strain, also reacts positively to anti-*H. hammondi* sera and has a variable degree of reactivity to anti-*T. gondii* sera. This pattern of reaction has been observed in cattle (Barr *et al.* 1990, 1991) and in goats (Barr *et al.* 1992). In other reports involving herbivores such as sheep, goats and horses, in which neosporosis has been observed, the parasite was referred to as *N. caninum* or *N. caninum*-like and details of immunohistochemical reactions against *H. hammondi* or different strains of *T. gondii* were not given (Dubey *et al.* 1990c; 1992a; Dubey & Porterfield 1990). On the other hand, recent work by Cole *et al.* (1993), using monoclonal antibody, suggested that there were no antigenic differences between the two strains and that the previous reports suggesting distinct immunologic patterns were due to the use of a polyclonal rabbit anti-*N. caninum* serum.

1.2.7.2 Epidemiology.

Since abortion and neonatal paralysis due to *Neospora* infection was first diagnosed in cattle in USA (Thilsted & Dubey 1989; Shivaprasad *et al.* 1989; Dubey *et al.* 1989a) and England (Dubey 1989), it has been identified in many countries throughout

the world including Australia (Dubey et al. 1990b; Obendorf & Mason 1990), New Zealand (Thornton et al. 1991), Holland (Wouda et al. 1992), Japan (Ogino et al. 1992), Canada (Bryan et al. 1994), South Africa (Jardine & Last 1993), and in several states of U.S.A. (Lindsay et al. 1993b). It is therefore likely to have a worldwide distribution.

Although *Neospora* sp. has been implicated as a cause of sporadic abortion (Dubey et al. 1990e), more importantly it is associated with multiple abortions (Thilsted & Dubey 1989, Lindsay et al. 1993b). In one report (Thilsted & Dubey 1989) 29 cows from a 240 drylot Holstein dairy herd aborted over a period of approximately 5 months. The fetuses were of 5-7 months gestation and *Neospora*-like organisms were observed in the brains of two fetuses and in the kidney of a third from a total of nine examined.

In North America, detailed retrospective studies using an immunoperoxidase technique revealed the presence of *Neospora* sp. in 19% of a total of 468 abortion cases submitted for investigation (Anderson et al. 1990; 1991).

In New Zealand, studies conducted at the Batchelar Animal Health Laboratory (Thornton et al. 1991) showed that 28 % of 320 cases submitted for diagnosis had histopathological features typical of protozoal infection. The presence of *Neospora* parasites was confirmed by immunohistochemistry in some cases.

Data from the New Zealand studies revealed that the average of the non-sporadic abortion rates on affected farms for the 1989-90 year was 6% with a maximum of 30% on one farm (Thornton et al. 1991). Higher values were reported by Anderson et al. (1992) in the U.S.A. where the prevalence of *Neospora* sp. abortion varied from 20% to 40% in eight counties studied.

The mean gestational age of the aborted fetuses was 5.4 months with a range of 3.5 to 8 months in the USA (Anderson et

al. 1990; 1991) while the New Zealand data suggested that abortions were more common early in gestation (Thornton *et al.* 1991). Abortions occurred at any time of the year (Anderson *et al.* 1990; Thornton *et al.* 1991) although Anderson *et al.* (1991) reported a peak of frequencies during spring and late autumn.

Although most of the abortions reported were from dairy farms, beef cattle can also be affected (Dubey *et al.* 1990e; Dubey *et al.* 1992c; Parish *et al.* 1987) but no breed predisposition has been identified.

In most of the literature reviewed, no other causes of abortion appear to interact with *Neospora* sp.. The exception is a report from Nebraska (Rogers *et al.* 1993) where *Neospora* spp., *Sarcocystis* spp. and an unidentified protozoan were believed to be responsible for 70 abortions in a 450 Holstein herd over July 1990 - September 1992 period.

Congenital *Neospora* sp. infections have been observed in five calves born to four Holstein cows that had previously aborted because of *Neospora* sp. infection (Barr *et al.* 1993). The cows did not demonstrate clinical abnormalities before delivery. Two of the five calves had clear clinical evidence of neurologic deficits consisting of ataxia, decreased patellar reflexes, and slight loss of conscious proprioception in either both pelvic limbs (one calf), or all four limbs (the other).

1.2.7.3 Clinical signs and pathology.

Cows infected with *Neospora* sp. show no clinical signs other than abortion. No specific gross findings have been reported in fetuses associated with *Neospora* sp. infection apart from autolysis and occasionally mummification (Thilsted & Dubey 1989; Nietfeld *et al.* 1992; Thornton *et al.* 1991; Barr *et al.* 1990).

The histological lesions in aborted fetuses are predominantly in the CNS and myocardium, although occasionally

lungs and kidneys are affected. Microscopically, affected brains have multifocal haemorrhage, multifocal gliosis in grey and/or white matter, perivascular lymphocytic cuffing and multifocal malacia, usually in white matter. Affected hearts have diffuse mononuclear myocarditis and epicarditis, and focal or diffuse myocardial necrosis with or without calcification (Barr *et al.* 1991; Anderson *et al.* 1991). In the CNS, the lesions have a random distribution but are more easily recognized in the brain stem because it undergoes autolysis less rapidly than the cerebrum. Early lesions consist of necrosis of the neuropil with or without haemorrhage but these lesions are difficult to recognize in an autolysed foetus (Dubey 1993).

Only occasional tachyzoites can be seen using light microscopy without the aid of immunohistochemistry.

Necrosis of the placental cotyledonary villi has been described associated with a *Neospora*-like abortion, but parasites are rarely observed (Shivaprasad & Dubey 1989).

There has been one report of a stillborn calf infected with *Neospora* sp. which had arthrogryposis (Dubey *et al.* 1990b). The caudal cervical and cranial thoracic segments of the spinal cord were asymmetric because of a marked unilateral reduction of ventral grey matter and focal cavitation. Lesions typical of *Neospora* sp. infection and tissue cysts were observed in the spinal cord.

Newborn calves infected with *Neospora* sp. have shown weakness and paralysis (O'Toole & Jeffrey 1987; Dubey *et al.* 1989a; Dubey 1989; Bryan *et al.* 1993; Barr *et al.* 1993; Dubey *et al.* 1992c; Parish *et al.* 1987). Usually, the calves were born without clinical signs, but these become apparent within the first week after birth (3-5 days) although Dubey *et al.* (1992c) have reported clinical neosporosis in a 4 week-old Hereford calf (Indiana USA).

Descriptions of clinical cases have reported that the affected calf's demeanour ranges from bright and alert to mildly depressed. Rectal temperature, heart and respiratory rates are normal and abnormalities are confined to the nervous and/or musculoskeletal systems (Dubey *et al.* 1989a; Dubey 1989; Bryan *et al.* 1994; Barr *et al.* 1993; Dubey *et al.* 1992c; O'Toole & Jeffrey 1987; Parish *et al.* 1987). In most affected calves the cranial nerve functions are normal, but one calf has been described in which the eyes were deviated ventromedially and the menace reflex was absent (Bryan *et al.* 1994).

The principal deficit observed is lack of limb proprioception, with the hind limbs more severely affected. Signs are compatible with cervical or generalized spinal cord lesions. No osseous or muscular deformities have been found and the calves spinal columns are radiographically normal. The cerebrospinal fluid may or may not show pleocytosis (Dubey *et al.* 1989a; Dubey 1989; Bryan *et al.* 1994; Barr *et al.* 1993; Dubey *et al.* 1992; O'Toole & Jeffrey 1987; Parish *et al.* 1987). Because of the paralysis, affected calves are generally unable to suckle.

Histopathological studies of these newborn calves have revealed that the damage was mainly confined to the CNS. The lesions were characterized by perivascular cuffing and randomly distributed areas of necrosis surrounded by inflammatory cells (glial or mononuclear) in both grey and white matter throughout the brain and spinal cord. Additionally, scattered foci of meningitis were also reported (Brian *et al.* 1994). Tachyzoites of *Neospora* sp. were seen in the brain and spinal cord. Only one calf showed additional lesions in the heart and skeletal muscles in which tachyzoites were present (Dubey 1992c).

1.2.7.4 Diagnosis and control.

For antemortem diagnosis in cattle, an indirect fluorescent antibody (IFA) test has recently been used successfully (Conrad *et al.* 1993b; Trees *et al.* 1994). The test confirmed infection

in both naturally and experimentally infected cows that aborted *Neospora*-infected fetuses. The titres were highest at the time of the abortion (1:320-1:5,640) and decreased within 150 days after the abortion episode to 1:160-1:640. The test was also able to detect precolostral antibodies in infected calves.

Immunohistochemical methods using polyclonal antiserum and the avidin-biotin peroxidase complex (ABPC) system are currently used to detect *Neospora* sp. parasites in tissue sections (Lindsay & Dubey 1989a; Bjerkås & Presthus 1988; Barr et al. 1991). Depending on the chromogen employed, the reactive parasites stain brown (3,3'-diaminobenzidine tetrahydrochloride [DAB] as chromogen) or red (3-amino-9-ethylcarbazole [AEC] as chromogen) and are readily visible in the blue counterstained tissue sections.

A mouse monoclonal antibody (MAB) prepared against *Neospora caninum* tachyzoites and bradyzoites which is reactive in the ABPC immunohistochemical test has also been developed recently (Cole et al. 1993). This monoclonal antibody did not react with *T. gondii* or 13 other genera of protozoa tested.

Neospora sp. can be also isolated from infected tissue by inoculation of cell cultures or laboratory animals (as discussed previously). Isolation of *Neospora* sp. from aborted bovine fetuses has been difficult because fetuses are generally moderately to severely autolysed at the time of abortion and protozoal tissue cysts are present in only a relatively small proportion of the infected fetuses (Barr et al. 1990). Previous studies have suggested that most of the protozoal cysts are adversely affected by autolysis (Barr et al. 1991).

Despite these problems, Conrad et al. (1993) recently succeeded in isolating the parasite from two bovine fetuses from a total of more than 100 examined over a two year period. Comparatively little autolysis together with a relative large

number of cysts appeared to be critical factors in the isolation (Conrad *et al.* 1993).

Control programs cannot be devised until the life cycle and reservoir host have been determined and the source of *Neospora* sp. infection in cattle is established.

1.3. *Toxoplasma gondii*.

Toxoplasma gondii is an intestinal coccidian of felids with an unusually wide range of intermediate hosts. Infection by this parasite is common in many warm blooded animals, including man and birds.

A comprehensive review of *T. gondii* and related apicomplexan protozoal infection in New Zealand has been recently published by Charleston (1994).

1.3.1. Structure and life cycle in comparison with *Neospora*.

The principal differential structures between *T. gondii*, *Sarcocystis cruzi*, and *Neospora* spp. are shown in Table 1.

TABLE 1: DIAGNOSTIC AND LIFE CYCLE FEATURES OF APICOMPLEXAN PROTOZOA THAT CAUSE ABORTION IN RUMINANTS.

Feature	<i>Neospora</i> spp.	<i>Toxoplasma gondii</i>	<i>Sarcocystis cruzi</i>
---------	----------------------	--------------------------	--------------------------

Tachyzoites (or Merozoites).

Morphology: Size Shape Staining	- 5-7x1-5 μm - ovoid, lunate or globular. - PAS	- 6x2 μ - crescent. - PAS +	- 4-8x1.2-1.5 μm - elongated. - PAS +
Structure: Parasitophor. vacuole Micropore Rhoptries	- absent or present. - absent (*). - present.	- present. - present. - present.	- absent. - absent. - absent.
Multiplication Location	- endodyogeny. - intracellular in various cell types.	- endodyogeny. - intracellular in various cell types.	- endopolygeny. - intracellular endothelial cells.

Tissue cyst.

Morphology: Size Capsule	- 30-100 μm - thick 1-4 μm , without septa - PAS	- 5-100 μm - thin 0,5 μm , without septa - PAS +	- < 500 μm - thin < 1 μm , with septa - PAS +
Location	CNS and eye	Any tissue (pref. muscle and CNS)	All striated muscle and CNS

Definitive host	Unknown	Felids	Canids
Prevalence of abortion	Common in bovine	Common in ovine	Occasional in bovine

(*) micropores have not been seen in tachyzoites in animals but have been found in tachyzoites grown in cell culture.

Unlike *N. caninum*, the life cycle of *T. gondii* is well established. Cats can acquire infection in three primary ways; by carnivorousism with the ingestion of cysts containing bradyzoites in the tissue of an intermediate host, by ingestion of oocysts previously passed by an infected cat and by congenital infection

resulting from parasitemia during pregnancy. Of these three methods carnivorousness is the most efficient form of transmission and is the only one which has been studied in detail.

After ingestion of tissue cysts, the bradyzoites are released. The free organisms penetrate the epithelial cells of the small intestine and undergo a series of asexual generations followed by a sexual cycle. The male gamete fertilizes the female gamete and a wall is formed around the latter giving rise to an oocyst, which passes unsporulated in the faeces. Sporulation occurs outside the body and oocysts become infectious within one to five days after excretion. This infective stage can survive in soil for several months (Dubey and Beattie 1988). The entire coccidian cycle of *T. gondii* can be completed within 3 days after ingestion of a tissue cyst. This enteroepithelial cycle is only observed in cats.

In all other hosts, and in cats simultaneously with the enteroepithelial cycle, an extraintestinal cycle occurs (sexual stages do not occur in non-feline hosts).

In the extraintestinal cycle, after ingestion of infected tissue or oocyst, the bradyzoites or sporozoites penetrate intestinal cells, multiply asexually as tachyzoites and spread to other organs. These tachyzoites multiply in almost any type of host cell until the cell is destroyed and more tachyzoites are released. Thus the tachyzoites may repeat the cycle in new host cells but will eventually encyst and develop into bradyzoites (Dubey and Towle 1986; Dubey and Beattie 1988).

Widespread natural infection is possible because a cat may excrete millions of oocysts after ingesting one infected mouse. This large excretion of oocysts usually occurs only during 1-3 weeks following the initial infection. After that a high level of resistance is established (Dubey and Beattie 1988). Oocysts can also be mechanically transmitted by invertebrates such as flies, cockroaches and earthworms, or dispersed by rain and snow.

Ingestion of oocysts is the only mode of transmission to herbivores (Frenkel 1990, Munday 1972).

1.3.2. Abortion in sheep and goats.

1.3.2.1. Sheep.

Toxoplasma gondii was first diagnosed as a cause of abortion in sheep in New Zealand in 1951 (Hartley *et al.* 1954) when it was known as New Zealand type 2 abortion. Since then the parasite has been recognized as a major cause of abortion in sheep in this country as well as Australia, Britain, Norway, Canada, the former USSR and in many states of North America and probably France (Dubey and Kirkbride 1984; Underwood and Rook 1992). Serologic studies have also shown the worldwide prevalence of *Toxoplasma* infection (Dubey and Towle 1986).

Toxoplasmosis is perpetuated in the rural environment mainly by bird/cat and rodent/cat cycles (Kirkbride 1985b; Dubey *et al.* 1986a). Sheep acquire infection by ingesting food contaminated with oocysts derived from cat faeces. The organism invades the gastrointestinal tract and regional lymph nodes and enters the bloodstream. Animals are usually asymptomatic at the time of initial infection (Hartley and Kater 1963).

In a susceptible pregnant ewe, tachyzoites of *T. gondii* infect the placenta and the foetus at the end of the period of parasitemia, which usually lasts 2 weeks after the ingestion of oocysts (Dubey and Sharma 1980). Thus transplacental infection of *T. gondii* can cause early embryonic death and resorption, foetal death and mummification, abortion, stillbirth, or neonatal death, depending largely on the stage of pregnancy at which the ewe becomes infected (Dubey and Towle 1988).

- Lesions in aborted material

Toxoplasma-induced lesions in sheep were described in detail by Hartley & Kater (1963), Beverley *et al.* (1971), and Buxton and Finlayson (1986). Toxoplasmosis differs from neosporosis in having characteristic placental lesions. In the placenta, the main changes are focal inflammation and necrosis of the foetal cotyledon; intercotyledonary areas are normal.

The characteristic gross placental lesion consists of white flecks or multiple white, chalky nodules up to 2 mm in diameter which are found in approximately half of the confirmed cases. These foci may be sparse and may occur in any level of the cotyledon and also not all cotyledons are affected to the same degree. Therefore, washing the cotyledon in order to expose the deeper lesions is a useful technique.

The lesions involve necrosis of mesenchymal cells in the foetal villi, oedema and infiltrations of mononuclear cells associated with hyperplasia and focal coagulative necrosis of the trophoblastic epithelium. Older lesions may show mineralization.

Single tachyzoites and clumps of organisms are usually present in small numbers. In older lesions, tachyzoites may be seen at the edge of the necrotic foci. *Toxoplasma* tissue cysts may be found occasionally (Dubey 1987a).

In the foetus, *Toxoplasma*-induced gross lesions are generally nonspecific. Small circumscribed discrete chalky nodules up to 1 mm in diameter have been described in the liver (Hartley and Kater 1963) but these are rarely seen.

Histologic lesions are more consistently found in the brain than in any other foetal tissue. Foci of leukoencephalomalacia and gliosis are the characteristic features of *T. gondii* infection. The malacic lesions consist of focal myelin loss, axonal swelling and degeneration. Older lesions may show some

peripheral gliosis and central calcification. Occasionally, mild to moderate nonsuppurative meningoencephalitis is seen. *Toxoplasma* tissue cysts are sometimes seen adjacent to foci of gliosis.

Liver and lung lesions are observed in a small proportion of the fetuses. Also occasionally interstitial myocarditis can be observed in some of the aborted lambs. Parasites are rarely seen in the lung or heart.

1.3.2.2. Goats.

In goats, the prevalence of *Toxoplasma* infection based on serological tests has been reported to vary from 0 to 100 % on different farms (Dubey *et al.* 1986b; Dubey 1987b; 1990b). A survey of 185 goats in New Zealand indicated prevalences ranging from 7% in kids to 37% in adults (Opel *et al.* 1991).

Goats, as with sheep, become infected in nature by ingestion of *T. gondii* oocysts passed in cat faeces; this is the major means of infection (Dubey & Sharma 1980; Dubey 1987b).

Among all the domestic food animals, goats are thought to be the most susceptible to *T. gondii* infection. In most adult goats, clinical effects are confined to reproductive failures and effects on fetuses, although, unlike sheep, *T. gondii* infection may produce a variety of lesions in adult goats. Encephalitis, nephritis, and perirenal steatitis, hepatitis, necrotizing abomasitis, enteritis, and cystitis have been described in adult goats (Mehdi *et al.* 1983; Chen & Alley 1987).

Toxoplasma gondii can cause early embryonic death, mummification, abortion, stillbirth, or birth of weak kids in goats (Munday and Mason 1979; Dubey 1981b; 1982a; Dubey *et al.* 1986b). Abortion due to *T. gondii* can take place in does of all ages (Dubey 1990b). Abortion probably occurs most commonly in does that acquire infection during pregnancy although unlike the

sheep, abortion may be repeated in the next gestation (Dubey 1981b; Dubey 1982a; Beverly & Watson 1970; Obendorf *et al.* 1990).

The placental lesions of *T. gondii*-induced abortion in goats are essentially similar to those seen in sheep, but the foci of placental necrosis may be smaller and less visible grossly (Munday and Mason 1979).

1.3.3. Toxoplasmosis in cattle.

Cattle are among the most resistant hosts of *T. gondii* (Dubey and Beattie 1988) although worldwide reports of natural and experimentally-induced *T. gondii* infection in cattle do exist. However, in most of these studies the means of diagnosis employed were of suboptimal specificity (Dubey 1986) and therefore the data need to be interpreted with caution.

There is only one report of clinical toxoplasmosis with isolation of *Toxoplasma*-like organisms from adult cattle. This occurred in the USA 40 years ago (Sanger *et al.* 1953) and the results of this study have not been confirmed. Abortion and neonatal mortality were also reported in cattle by the same authors. However, subsequent attempts to induce abortion in cattle experimentally, using *T. gondii*, were largely unsuccessful (Dubey 1986; Stalheim *et al.* 1980; Munday 1978).

The recognition of *N. caninum* and *S. cruzi*, as abortifacient organisms in cattle with their structural similarity to *T. gondii* (Thilsted and Dubey 1989; Dubey and Beattie 1988) now casts considerable doubt on the earlier findings and it seems likely that these cases were misdiagnosed.

Serum antibodies to *T. gondii* have been reported in cattle worldwide and the data have been reviewed and tabulated by Dubey (1986). Because of the problems with test specificity, the actual prevalence rates are likely to be lower than indicated (Dubey 1990c). It is now known that the Sabin-Feldman dye test (DT),

which is considered the most reliable test for evidence of *Toxoplasma* infection in human beings, is unsuitable for diagnosis in cattle because a globulin present in bovine serum causes false-positive results (Dubey *et al.* 1985, Dubey 1986; 1990c).

The sensitivity and specificity of other serotests for the diagnosis of toxoplasmosis in cattle have been evaluated (Dubey *et al.* 1985). Indirect hemagglutinating antibody (IHA) and immunofluorescence antibody (IFA) tests, together with the Sabin-Feldman dye test (DT) were of poor specificity; only the modified agglutination (MDA) test detected specific antibodies.

Whether or not *T. gondii* causes clinical disease in cattle and whether or not they are important in the epidemiology of the disease are still uncertain. From the limited information available it can be said that well-documented cases of abortion and critical evidence of clinical disease in cattle does not exist. Only recently has *T. gondii* been isolated from the intestinal wall of a naturally-infected cow in the USA (Dubey 1992b).

1.4. *Sarcocystis* spp.

Sarcocystis spp. are among the most prevalent parasites of livestock. In cattle and sheep virtually all adult animals are infected. The organism also infects many other mammals, birds, cold-blooded animals, and man.

1.4.1. Structure and life cycle *Sarcocystis* spp. in comparison with *Neospora* spp..

The characteristic structural features of *Sarcocystis cruzi* in comparison with *Neospora* spp. and *Toxoplasma gondii* are shown in Table 1.

Sarcocystis has an obligatory prey-predator, two-host life cycle. Asexual stages develop only in the intermediate host which

in nature is often a prey animal. Sexual stages develop only in the definitive host which is carnivorous. The intermediate and definitive host vary for each species of *Sarcocystis*. For example, there are three named species of *Sarcocystis* known to infect cattle; *S. cruzi*, *S. hirsuta*, and *S. hominis*. The definitive host for these species are canids, felids and primates respectively (Briggs & Foreyt 1985, Fayer & Dubey 1986).

Sarcocystis cruzi is the most common and the most pathogenic of these species (Fayer et al. 1976; Dubey et al. 1982). Therefore it will serve as the example in the following description of a typical life cycle. Dogs, coyotes, red foxes and possibly wolves, jackals and raccoons are the definitive hosts for *S. cruzi*, whereas the North American bison and cattle are the intermediate hosts (Dubey 1982b; Fayer et al. 1982).

The definitive host becomes infected by ingesting the encysted form of the parasite in the musculature of intermediate hosts. Bradyzoites liberated from the sarcocysts, penetrate the mucosa of the small intestine and transform into macro- and micro- gamonts. The microgamete consists of a compact nucleus and two flagella. Microgametes liberated from the microgamonts actively move to the periphery of the macrogamont and fertilization takes place which gives rise to the zygote which develops into an oocyst (Fayer et al. 1982).

Oocysts sporulate in the intestinal lamina propria and the oocyst wall, which is delicate, usually ruptures to release the two enclosed sporocysts. These are then passed in the faeces. Sporulated sporocysts are immediately infective to the intermediate host and this is a unique feature of *Sarcocystis* spp.

Following ingestion of a sporocyst by the intermediate host, sporozoites are released in the small intestine, where they penetrate the intestinal mucosa and eventually enter into arterioles. The sporozoites travel to the mesenteric lymph nodes

and embed in the endothelial and subendothelial cells where first-generation schizonts (meronts) are formed (Reiten *et al.* 1966). Each meront contains slightly more than 100 merozoites (Dubey 1976). These first-generation merozoites then differentiate into second-generation schizonts which give rise to about 25 merozoites. These are seen most commonly in the glomeruli of the kidney (Dubey *et al.* 1980; Dubey 1981a).

Merozoites travel in the peripheral blood and enter striated muscle fibres (diaphragm, oesophagus, heart, skeletal muscle, tongue) where they encyst. The immature sarcocyst is small and contains metrocytes. When metrocytes eventually differentiate into bradyzoites which are infectious for the canine definitive host (about 10 weeks after inoculation), the sarcocyst is considered mature. Immature sarcocysts and schizonts are not infectious for the definitive host (Dubey 1976; Briggs & Foreyt 1985). Sarcocysts may persist for the life of the host, but many begin to disappear after 3 months postinoculation. The mature sarcocysts of *S. cruzi* are microscopic and have a thin wall covered with fine hair-like protrusions (Dubey & Fayer 1983).

1.4.2. Sarcocystosis in cattle.

The geographic distribution of *Sarcocystis spp.* of cattle is worldwide and the prevalence of infection is high. Cases of natural clinical sarcocystosis in cattle have been reported in Canada, England, Ireland, Norway, Australia, and the U.S.A. (Dubey *et al.* 1989).

A variety of clinical signs have been observed during infection in cattle. They may develop fever (≥ 40 C), anorexia, weight loss, weakness, muscle twitching, prostration and in some cases death (Johnson *et al.* 1975). If the animal is lactating a decrease in milk production is usual (Fayer *et al.* 1983). As infection becomes chronic, other signs also become apparent. Growth is adversely affected the animals become hyperexcitable, they hypersalivate and lose hair especially on the neck, rump and

tail switch (rat-tail appearance) (Giles et al. 1980). Some animals become emaciated and some eventually develop CNS signs including recumbency, opisthotonus, nystagmus, a cycling gait while laterally recumbent and occasionally death (Fayer & Dubey 1986).

- Sarcocystis-induced abortion.

Although abortion and foetal death can result from both experimental (Fayer & Dubey 1986; Fayer et al. 1976) and natural *Sarcocystis* infection, (Corner et al. 1963; Dubey & Bergeron 1982; Hong et al. 1982; McCausland et al. 1984;), it should be emphasised that abortion has been reported in most animals that develop clinical sarcocystosis, whereas most infected animals without signs of infection carried the foetus to term (Dubey 1981; Leek & Fayer 1979). Based on the parasite location and lesions, several possible mechanisms have been hypothesized to explain the pathogenesis of *Sarcocystis* spp. abortion (Dubey et al. 1989) but it is still not clear if abortion occurs through a direct effect of the parasite on the foetus or as a by-product of compromising the general health of the dam.

Sporadic cases of bovine abortion and neonatal mortality associated with sarcocystosis have been reported in New Zealand (Thornton 1987; Vickers & Brooks 1983), Australia (McCausland et al. 1984; Munday et al. 1976), and in the U.S.A. (Dubey & Bergeron 1982).

In naturally-infected bovine foetuses, parasites are found in virtually all organs, but are most often observed in the brain. Lesions and parasites are also found in the placenta (Corner et al. 1963; Dubey & Bergeron 1982). By contrast, results from experimentally-infected animals have indicated that although *Sarcocystis* spp. may be present in the maternal placenta, it rarely infects the foetus or foetal membranes (Dubey et al. 1988).

The brain lesions consist of a nonsuppurative encephalitis or meningitis, with small foci of glial cells surrounding a central necrotic focus. These are located throughout the grey and white matter of the cerebrum, cerebellum, or brainstem, with some perivascular mononuclear cell infiltration and occasional microthrombi in vessels surrounding the foci. Other affected foetal organs have lesions similar to those of infected postnatal animals. These include a nonsuppurative myocarditis, pneumonitis, hepatitis and renal glomerulitis which is accompanied by focal necrosis and haemorrhage (Dubey & Bergeron 1982).

Immature and mature schizonts and free merozoites can be found, usually within endothelial cells of foetal capillaries and occasionally free in the lumen of vessels or in neural tissue.

Free merozoites and schizonts, usually associated with lesions, have been observed in maternal or foetal placentas of some cattle. Haemorrhage, necrosis and calcification of placental villi epithelial cells and of the intercotyledonary connective tissue have also been described in natural sarcocystosis.

Sarcocystis hirsuta (*S. bovifelis* (Heydorn et al. 1975) is mildly pathogenic to calves. It is not known whether this species can cause abortion (Dubey 1983b).

1.4.3. Sarcocystosis in sheep.

There are four *Sarcocystis* species in sheep, two macrocystic species, *S. medusiformis* and *S. ovifelis* which have a sheep-cat cycle and two microcystic species, *S. arieticanis* and *S. tenella* which usually have a sheep-dog cycle. The macrocystic species are thought to be non-pathogenic (Jeffrey 1993; Dubey et al. 1986c).

Naturally occurring *Sarcocystis* abortion in sheep has never been reported and no evidence of congenital infection has been found either experimentally or naturally. It is therefore likely to be a very rare event.

Abortion in sheep inoculated with *S. tenella* has been reported once (Leek & Fayer 1977). Contradictory evidence was produced by Cole (1978) and Munday (1981) who were not able to produce abortions in ewes inoculated with the organism.

1.4.4. Sarcocystosis in goats.

The goat is thought to be the intermediate host of three species of *Sarcocystis*: *S. capracanis*, *S. hircicanis*, and *S. moulei*.

Sarcocystis capracanis has the dog, coyote, red fox and crab-eating fox as definitive hosts and is reported to be the most pathogenic species of *Sarcocystis* in goats. It can cause fever, weakness, anorexia, weight loss, tremors, irritability and death (Dubey 1981b; Dubey et al. 1981; Collins & Charleston 1979; Dubey et al. 1984).

Sarcocystis capracanis has also been reported to produce abortion in pregnant does (Dubey 1981b). Since no *Sarcocystis* were found in foetal tissues and abortion occurred in animals acutely affected without specific lesions, it is likely that the abortion in this case was the result of fever and placental insufficiency.

CHAPTER 2.

EXAMINATION OF TISSUES INFECTED WITH *NEOSPORA* SPP.

2.1. Dogs.

2.1.1. Introduction.

Neosporosis in dogs is a protozoal disease similar to *T. gondii* infection (Bjerkås & Dubey 1991; Dubey *et al.* 1988a). Cases of naturally-occurring neosporosis in dogs have now been reported from all over the world (see literature review, Chap. 1).

Dogs may be infected with *Neospora* spp. at any age, but the most severe cases have involved congenitally-infected pups with several animals from the same litter affected (Dubey *et al.* 1988a; Mayhew *et al.* 1991; Hay *et al.* 1990; Jacobson & Jardine 1993). Most congenitally-infected pups do not show any clinical signs at birth, and it is not until 3-6 weeks of age that the disease becomes evident. No breed or sex predisposition has been associated with *Neospora* infection in dogs (Dubey 1992a).

The spectrum of clinical illness and lesions seen in neosporosis makes it difficult to distinguish from toxoplasmosis and for this reason it is now thought that many diagnoses of toxoplasmosis made in the past may have been neosporosis. The recent development of immunologic techniques (Lindsay and Dubey 1989a) however, has allowed the presence of the parasite to be confirmed in dogs from several parts of the world (Dubey 1992a).

Although it is known that neosporosis occurs in cattle in New Zealand, the disease has not been recorded in dogs. The present investigation was therefore initiated in order to find whether or not *N. caninum* could be identified in dogs in New Zealand with a possible history of protozoal infection. The case material reviewed consisted of tissues held in the archives of the Department of Veterinary Pathology & Public Health, Massey University collected over the past 22 years.

2.1.2. Materials and methods.

- Case material.

Case histories, laboratory data, and haematoxylin and eosin (H&E)-stained CNS tissue sections from 15 dogs were used in this study. The previous diagnoses of these cases included; granulomatous meningoencephalitis (GME) (11 cases), polyradiculoneuritis (1 case), toxoplasmosis and distemper encephalitis (3 cases).

- Light and transmission electron microscopy.

Tissue sections of CNS from selected original paraffin-embedded blocks were cut at 5 μ m and were examined after staining with periodic acid-Schiff (PAS) and H&E. Sections from the brain of one dog (11383) were de-paraffinized and processed for transmission electron microscopy by standard methods (Speer and Dubey 1982).

- Immunoperoxidase staining procedures.

The technique used was that described by Lindsay and Dubey (1989). An Avidin Biotin Peroxidase Conjugate (ABPC) anti-goat IgG kit (Veterinary Medical Research and Development, Inc. Pullman, WA) was used to detect specific binding of goat antiserum to *N. caninum*. Tissue sections were deparaffinized with xylene, rehydrated in ethanol, and treated with 5% hydrogen peroxide in pH 7.2 phosphate-buffered saline solution (PBS) for 30 min. to inhibit endogenous peroxidase activity. Sections were washed in PBS then incubated in diluted goat serum for 30 min. to block non-specific binding, before incubating in specific antisera for 1hr. Unbound antibodies were removed by washing sections in PBS. Sections were then incubated with biotinylated goat anti-rabbit IgG for 30 min. then washed in PBS and incubated in avidin-biotin-peroxidase reagent for 30 min. before washing in PBS and incubating for 3 min. in 3-amino-9-ethylcarbazole

(AEC) chromogen in N,N-dimethylformamide. The sections were finally washed in distilled water, counterstained with haematoxylin, dehydrated in ethanol and mounted with a coverslip. Anti-*N. caninum* serum was used at 1:3,000 dilution, although sometimes, when a strong reaction was desirable, it was used at 1:2,000 dilution.

Simultaneously, rabbit anti-*Toxoplasma gondii* primary antibody (BioGenex Laboratories, San Ramon, CA, USA) sera were run in parallel with another set of sections. Appropriate positive tissue sections (from experimentally-induced infections) and negative controls were evaluated with each set of sections for both anti-*N. caninum* and anti-*T. gondii* sera.

2.1.3. Results.

Of the 15 cases examined in the present study, 5 exhibited different stages of apicomplexan parasites in the histological sections (Table 1).

***Neospora*-infected dogs.**

i) Case histories.

The age, breed and sex of affected dogs is given in Table 1. Neurological syndromes involving the pelvic limbs were the predominant clinical feature reported in all the three dogs. These ranged from ataxia to paralysis of the hind legs. Other signs included urinary retention, pain on manipulation of the neck and head as well as change in temperament and demeanour. The animals were humanely killed at the time of onset of posterior paralysis. One animal (N° 4741) had a history of vaccination against canine distemper/canine hepatitis virus 14 days before the development of clinical signs.

Routine haematological and clinical chemistry profiles were all normal except the CSF. In two of the dogs, CSF examination

Table 1: Summary of results of immune-staining of CNS tissue for *Neospora caninum* and *Toxoplasma gondii*.

Case No	Age	Breed	Sex	Clinical Signs	Original Diagnosis	Immune stain <i>N.caninum</i>	<i>T.gondii</i>
4741-72	1y7m	Labrador	F	Hind limb paralysis	Distemper/ Toxoplasmosis	+	-
6951-73	4m	Dachshund	F	Sudden death	Distemper/ Toxoplasmosis	-	+
6519-74	2½m	Cross bred	M	Multisystemic	Toxoplasmosis/ Distemper	-	+
11383-78	1y	WHW Terrier	M	Prog. hind limb paresis.	GME	+	-
15777-84	6y	WHW Terrier	M	Hind limb ataxia	GME	+	-

GME: Granulomatous meningo encephalitis.

revealed an increase in the number of cells (mainly lymphocytes although a few eosinophils and macrophages were also present).

ii) Pathological findings.

- Gross pathology.

The necropsies of all three dogs revealed no major abnormality. One dog (N° 11383) had a single grey, unilateral focus 4 mm in diameter in the medulla oblongata behind the cerebellar peduncle and anterior to the obex in the dorsal part of the brain stem. An apparent mild cerebellar atrophy was reported in another animal (N° 15777).

- Histopathology.

A common pattern of lesions was present in the CNS of all the three dogs. Sections of the brain and spinal cord of all dogs showed multifocal, non-suppurative meningoencephalomyelitis. In every case the lesions were more severe in the spinal cord sections than in the brain. The meninges showed marked infiltration of lymphocytes and mononuclear cells and the underlying white matter was also intensely infiltrated with lymphocytes, plasma cells, macrophages and immature mononuclear cells. Focal areas of necrosis, perivascular cuffing and neurone degeneration were also evident in different sections of the spinal cord mainly in the periphery of the white matter (Fig 2.1). Similar inflammatory foci containing proliferating blood vessels were observed in the brain stem. Spherical protozoal cyst-like, extracellular structures some of which had thick walls were seen at the periphery of glial nodules without a cellular reaction associated with them (Fig 2.2). Wallerian degeneration was also present in the spinal cord and nerve rootlets. The rest of the organs studied (bladder, intestine, kidney, myocardium, liver, adrenal) had no histological lesions apart from the lungs of one dog (N° 11383) in which small granulomatous foci, composed

Figure 2.1. Section of spinal cord from dog (N° 11383) infected with *N. caninum*. There is severe myelitis and protozoan organisms (arrows) are scattered throughout the neuropil. H&E x65

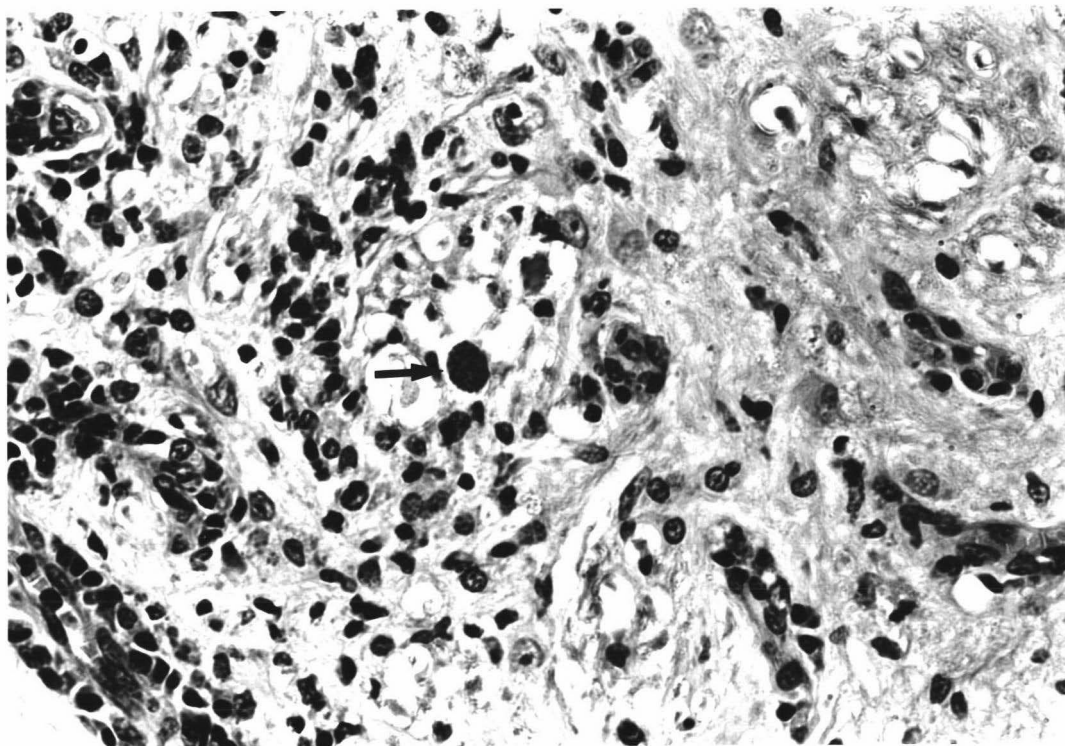
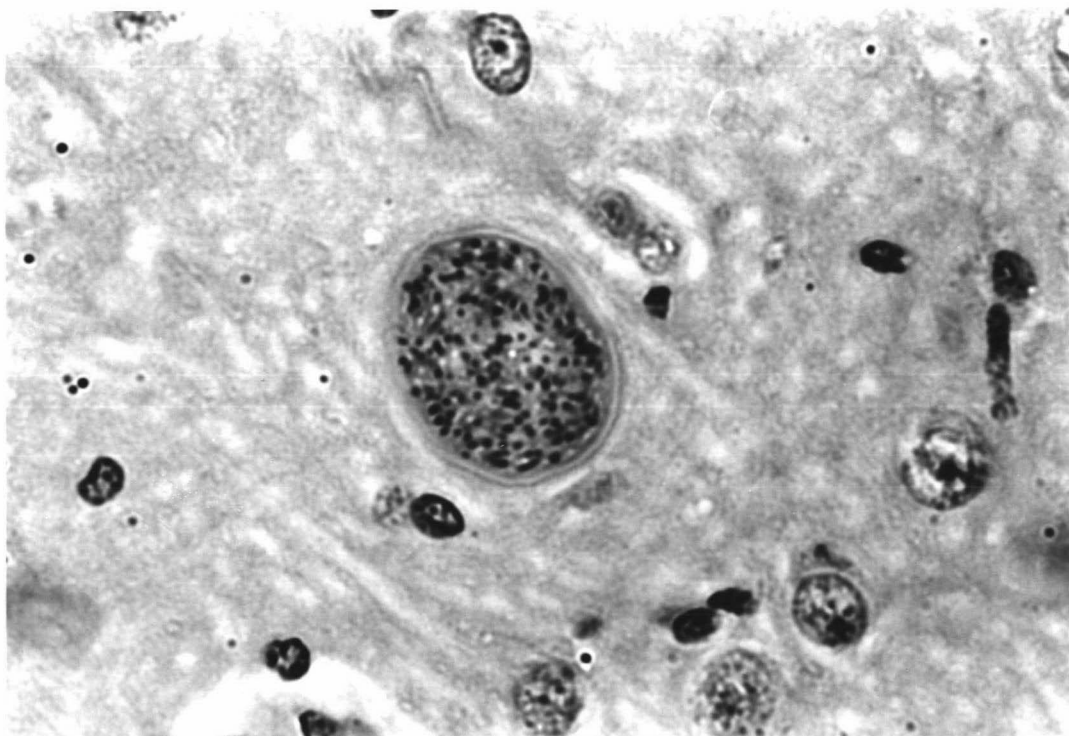


Figure 2.2 *Neospora caninum* cysts in the spinal cord of a dog (N° 11383) without any associated inflammatory reaction. Note the thick capsule. H&E x650



of macrophages, lymphocytes and plasma cells, were associated with the blood vessels in the lung parenchyma.

- Electron microscopy.

Ultrastructurally, the tissue cysts found in the brain of case N° 11383 possessed a thick wall and numerous bradyzoites (Fig 2.3 & 2.4). The bradyzoites contained a single central nucleus, a conoid, numerous rhoptries, amylopectin granules and micronemes arranged perpendicular to the plasmalemma (Fig 2.5 & 2.6).

iii) Immunohistochemistry.

The immunohistochemical examination of sections of CNS revealed that the protozoal structures reacted with *N. caninum* antiserum but did not react with the *T. gondii* antiserum. The technique allowed individualised group and/or individual zoites (Fig 2.7 & 2.8) as well as degenerative cyst-like structures associated with the inflammatory foci to be identified.

After the immunohistochemical staining, a careful re-examination of the H&E sections revealed occasional thick-walled cysts in the *Neospora*-positive cases. Their number varied with each case, but they were always outnumbered by the thin-walled structures.

The positive control sections for both *N. caninum* and *T. gondii* antisera showed strong immunohistochemical staining in contrast to the negative controls where no reaction was observed.

Figure 2.3. Ultrastructure of a tissue cyst ($10.9 \times 6.3 \mu\text{m}$) of *N. caninum* in the brain of case N° 11383. Note the thick ($0.6 \mu\text{m}$) granular, cyst wall (w) and bradyzoites (b). TEM $\times 7,800$

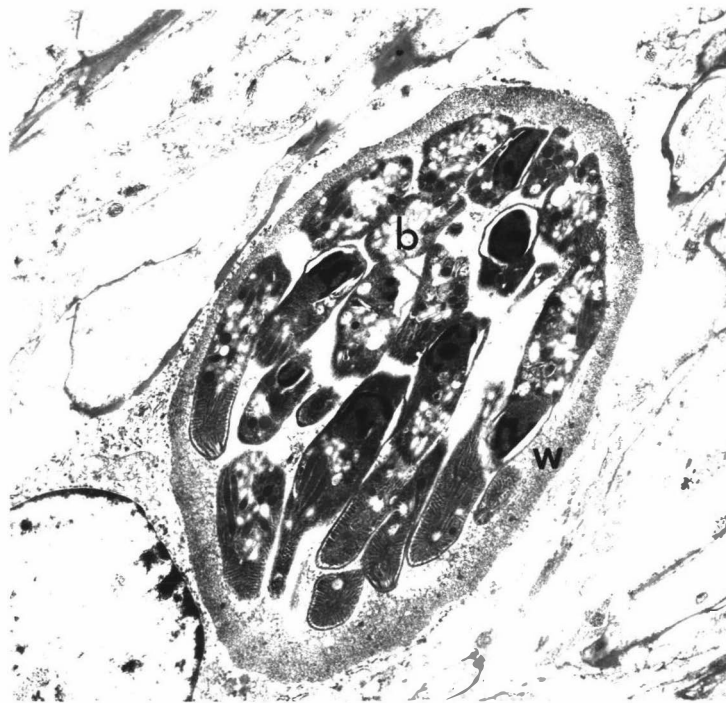


Figure 2.4. Ultrastructure of part of a large tissue cyst ($26 \times 16 \mu\text{m}$) of *N. caninum* in the brain of a dog (N° 11383). The cyst wall (w) is $1.7 \mu\text{m}$ thick and the cyst contain numerous bradyzoites (b). TEM $\times 5,200$

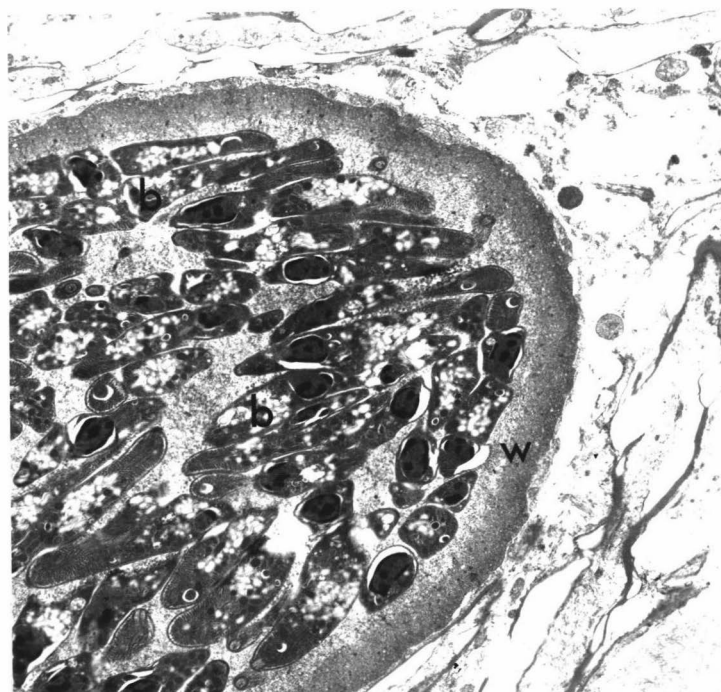


Figure 2.5. Higher magnification of part of the cyst shown in Fig. 2.4. Nuclei (n), micronemes (m), electron dense bodies (d) and amylopectin granules (a). TEM x11,200

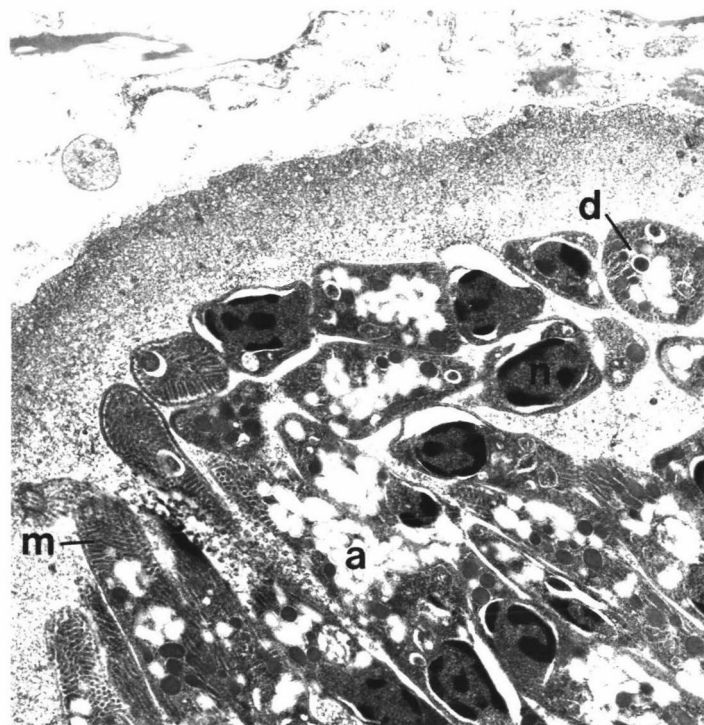


Figure 2.6. Anterior end of a *N. caninum* bradyzoite, with conoid (c), many micronemes (m), rhoptries (r) and an electron dense body (d). TEM x48,600

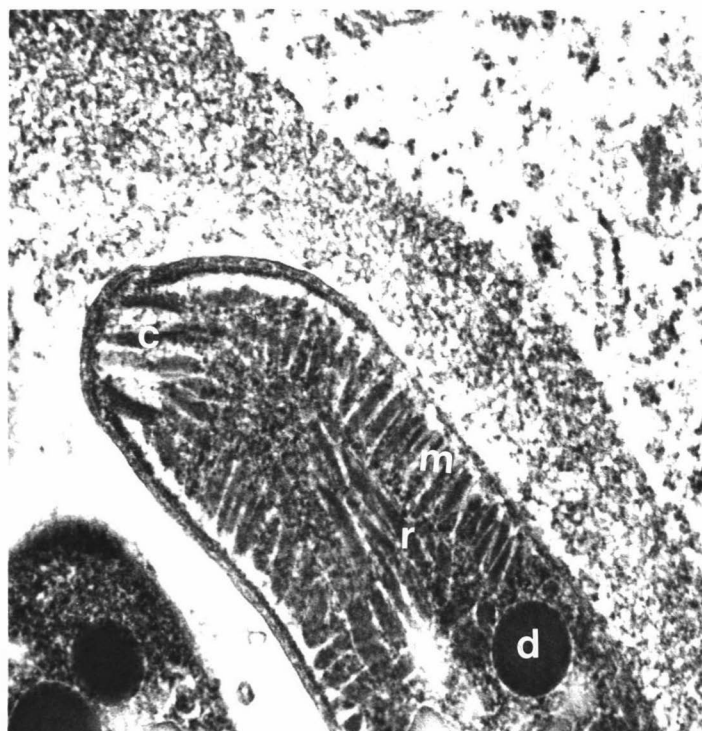

Figure 2.7. Group of zoites of *N. caninum* (arrow) and individual zoites (arrow head) in a dog. ABTC x680


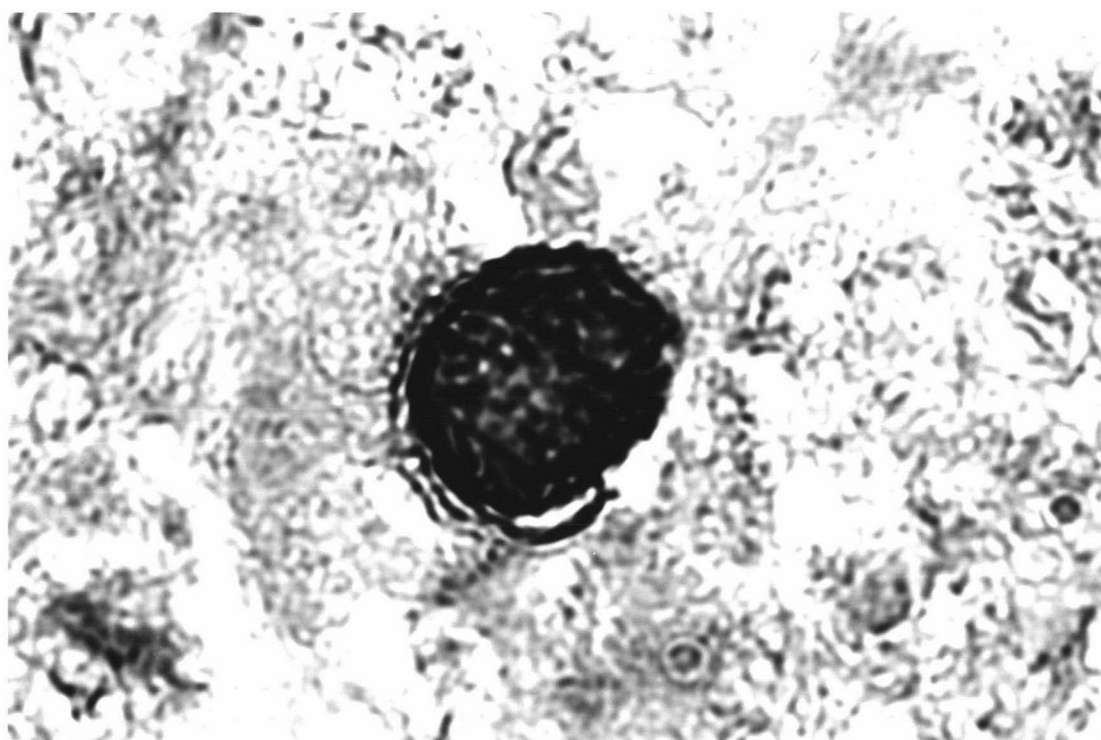


Figure 2.8. *N. caninum* cyst-like structure in dog brain. ABPC x680



- *Toxoplasma*-infected dogs.

i) Case histories.

The age, breed and sex of the affected animals is shown in Table 1. One dog (N° 6519) suffered a generalized illness characterized by vomiting, diarrhoea, loss of appetite, dyspnea and photophobia and was destroyed after no improvement in signs. The other (N° 6951) was found dead without any symptoms observed.

ii) Pathological findings.

- Gross pathology.

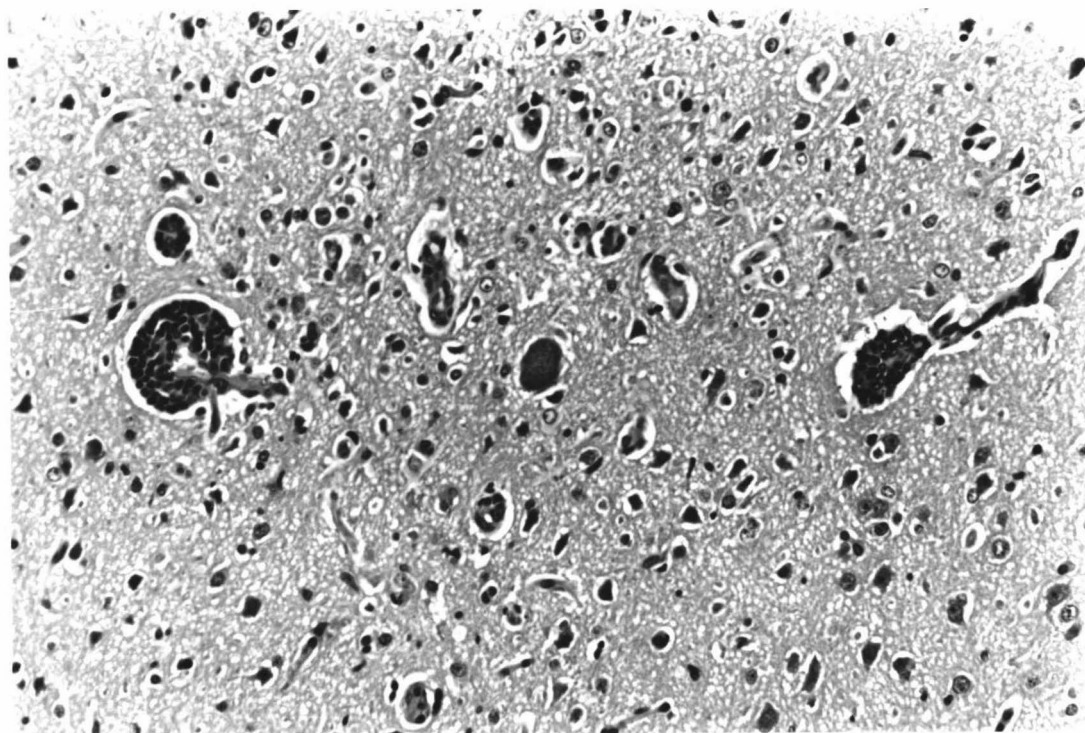
In both animals the lungs showed gross lesions. They were pale, consolidated and oedematous.

- Histopathology

Microscopically, both animals showed similar lesions that were confined to the CNS and lungs. The brain and spinal cord showed scattered, mild foci of gliosis and neurone degeneration. Perivascular spaces around occasional vessels were moderately infiltrated with mononuclear cells. Several tissue cysts were observed in different areas of the CNS sometimes associated with a mild non-suppurative inflammatory reaction (Fig 2.9). The lungs showed a very severe chronic interstitial pneumonia. Extensive areas of the parenchyma were infiltrated with mononuclear cells, including numerous macrophages and giant cells.

In one case (N° 6519), numerous intracytoplasmic eosinophilic inclusions were evident throughout the lungs and kidneys. Also present were occasional thin-walled protozoal cyst-like structures throughout the lungs.

Figure 2.9. Section of the brain from dog N° 6519 infected with *Toxoplasma gondii*. Note the mild inflammatory reaction associated with the parasites. H&E x65



iii) Immunohistochemistry.

The protozoan cysts and tachyzoites stained strongly with anti-*T. gondii* serum and showed no reaction with the anti-*N. caninum* serum (Fig 2.10).


By light microscopy, the parasites appeared similar in structure and it was not possible to differentiate between *T. gondii* and *N. caninum*.

Other dogs with meningoencephalomyelitis.

Sections from cases N^{os} 9823-77, 9942-77, 10201-77, 10666-78, 11707-79, 13710-81, 13438-81, 19558-88, 23642-93, 24241-94 showed no evidence of protozoal parasites in H&E sections. The essential histologic features of these cases were the perivascular aggregations of mononuclear inflammatory cells in different areas of the CNS. These areas were localized or in some cases, diffusely distributed. In most cases the meninges were infiltrated with similar cells and the adjacent white matter was undergoing necrosis. In the majority of these cases, the perivascular cuffing was composed of cells such as lymphocytes, monocytes, plasma cells and histiocytes but in some cases the cells were immature mononuclear cells. These histological features are in accordance with the description of granulomatous meningo-encephalitis in dogs (Cordy 1979; Alley et al. 1983).

Despite the absence of protozoal organisms, the immunocytochemical staining procedures for *T. gondii* and *N. caninum* were carried out on several sections from each case (a minimum of four sections per case). Sections from cases N^{os} 9823-77, 9942-77, 10201-77, 10666-78, 11707-79, 13710-81, 13438-81, 19558-88, 23642-93, 24241-94 did not react with either anti-*T. gondii* nor anti-*N. caninum* sera.

Figure 2.10. Dog brain infected with *T. gondii* showing typical cyst. ABPC x650



2.1.4. Discussion.

In this study, the occurrence of *N. caninum* infection as a primary pathogen of dogs in New Zealand is reported for the first time. Of the three cases of neosporosis identified in dogs, one was previously suspected to have had distemper/toxoplasmosis and the others granulomatous meningoencephalitis. In view of these findings, *N. caninum* infection should be considered as a differential diagnosis in dogs in New Zealand with encephalitis. The diagnosis of neosporosis was based in immunocytochemical reactivity of the parasite with anti-*N. caninum* sera and was supported by the absence of reactivity against anti-*T. gondii* sera, the occurrence of characteristic clinical signs and the histological nature of the lesions.

It is generally agreed that because of the morphological similarity of *T. gondii* and *N. caninum*, immunohistochemistry and/or electron microscopy are the best means of differentiating the infections (Dubey *et al.* 1988a,b; Hay *et al.* 1990; Uggla *et al.* 1989; Hilali *et al.* 1986; Cuddon *et al.* 1992; Dubey & Lindsay 1993; Mayhew *et al.* 1991; Lindsay & Dubey 1989a; Sheahan *et al.* 1993). In the current retrospective study, a distinctive histopathologic pattern was also observed for each disease. In the H&E stained sections of the CNS, more severe lesions with a wider distribution were present in the *Neospora*-infected dogs. The degree of mononuclear infiltration and the extent of areas of malacia were distinctive features of the *Neospora* infected material. By contrast, a mild to moderate inflammatory reaction was associated with the *T. gondii*-infections. In addition, in all the cases of neosporosis, the lesions involved extensive areas of the spinal cord. In the brain, the lesions tended to localise at the base of the brain stem where cranial nerves originate and in the spinal cord the lesions tended to be more pronounced near the peripheral nerve rootlets. This distribution concurs with the polyradiculoneuritis previously described in *Neospora* infection by Cummings *et al.* (1988). Furthermore, the lesions observed in the lungs of one case (N° 11383) resembled the granulomatous

types of *Neospora*-lesion previously described in parenchymatous organs by Dubey *et al.* (1988a). Unfortunately no muscle sections of the affected limbs were available for histological examination in these cases.

Tissue cysts of *N. caninum* are only found in the CNS (Dubey *et al.* 1992a). However, tissue cysts of *T. gondii* can be observed in many other organs (Dubey 1985) as was the case in dog N° 6519 where several thin walled, cyst-like structures were found in the lung. The thickness of the cyst wall in tissues is reported to differ in these two protozoa (Dubey *et al.* 1990) in that those of *Neospora* are described as thick-walled. In the present investigation, thin-walled *Neospora* cysts often outnumbered thick-walled cysts indicating that this criterion could not be confidently used to differentiate between the two parasites. Perhaps the thickness of the wall varies with maturity of the cyst or represents a different stage of development (Dubey 1992a).

The ultrastructural study of the protozoal cysts revealed the characteristic features of *N. caninum* previously described (Dubey *et al.* 1988a,b, Lindsay *et al.* 1993a) thus providing further support for the diagnosis of *Neospora* encephalomyelitis.

The presence of abnormal CSF findings in the *Neospora* cases is in agreement with previous reports (Dubey *et al.* 1988a; Cuddon *et al.* 1992) and concurred with the histopathological findings. The cell types seen on CSF analysis were a mixture of mononuclear cells and eosinophils or mononuclear cells and macrophages. Eosinophils were reported in the CSF of two pups with *Neospora*-associated encephalomyelitis (Cuddon *et al.* 1992) and in two cases of *Neospora*-associated polymyositis (Dubey *et al.* 1988a). *Neospora*-infected dogs with normal CSF have also been reported (Hay *et al.* 1990, Dubey *et al.* 1988a).

It is noteworthy that all the *Neospora* infected dogs showed some degree of neuromuscular deficit in the hind limbs. This

finding is in agreement with previous reports of canine neosporosis (Dubey *et al.* 1988a,b; Wolf *et al.* 1991; Cuddon *et al.* 1992) which indicated that hind limb paralysis was the most common presenting sign. It is more evident in young animals although it can also be observed in older dogs (Dubey *et al.* 1992a) as in the present study. Dogs with progressive hind limb paresis/paralysis may be depressed or alert but they can survive, with hand feeding and supportive care for several months (Dubey and Lindsay 1993). Muscle flaccidity, muscle atrophy and other dysfunctions, reported as clinical findings in neosporosis in dogs by other authors (Hay *et al.* 1990; Mayhew *et al.* 1991; Cuddon *et al.* 1992), were not described in this study. However, the clinical signs are somewhat variable since *N. caninum* does not affect all dogs with the same severity and infection is not always fatal (Dubey & Lindsay 1993).

It was interesting that in one case (N° 4741) the onset of clinical neosporosis followed a canine distemper/canine hepatitis vaccination. A similar case was reported by Sheahan *et al.* (1993) following routine vaccination against canine distemper, canine hepatitis, canine parvovirus and leptospirosis. Toxoplasmosis has also been recorded previously in dogs following vaccination with modified canine distemper virus. The pathogenesis of these episodes is not explained but it has been speculated that they result from temporary immunosuppression caused by infection with the attenuated vaccine virus (Dubey 1985).

In most circumstances canine neosporosis is confined to the CNS. However, generalized disease has also been described (Dubey *et al.* 1988a) with involvement of virtually all organs, including the skin. This generalized pattern is more commonly observed in adult dogs (Smith 1993). Unfortunately, we could not perform immunocytochemistry on organs other than CNS in this study, but the granulomatous lesion in the lungs of one dog (N° 11383) is suspected to have a protozoal cause.

The marked mononuclear cell infiltration seen in the *Neospora* lesions of the CNS and spinal cord is suggestive of an immune-mediated reaction and is invariably associated with ruptured or degenerating cysts and/or individual zoites (Mayhew *et al.* 1991, Dubey 1993). By contrast, intact tissue cysts did not seem to evoke any cellular reaction. It is not known if toxic products are released by *Neospora* spp. organisms.

The most severe cases of canine neosporosis have been reported in natural congenital infections (Dubey & Lindsay 1993). In the present study all the dogs were adult but is not known if the disease was the result of a new infection or the reactivation of dormant cysts. The possibility of reactivation of latent infection is supported in the literature by reports that subclinically infected bitches have given birth to more than one litter of infected pups (Dubey *et al.* 1988b; Bjerkås & Presthus 1989; Dubey *et al.* 1990f; Sheahan *et al.* 1993) although the dam may also be reinfected during pregnancy.

The lesions in the ten dogs examined without protozoal parasites are consistent with those of granulomatous meningo-encephalomyelitis. Previous studies have failed to identify the cause of this entity (Cordy 1979, Braund *et al.* 1978, Alley *et al.* 1983). In these reports, agents capable of causing granulomatous disease in dogs such as tuberculosis, toxoplasmosis, and fungal infections together with distemper virus were not found. Our study showed that none of the sections tested reacted with the anti- *N. caninum* or *T. gondii* sera used.

The two *T. gondii* cases (N^os 6951 and 6519) were initially diagnosed as distemper and sections from one dog (N^o 6519) contained intracytoplasmic viral inclusion bodies in various organs typical of this disease. This is consistent with the hypothesis that most clinical cases of toxoplasmosis occur in dogs with concurrent distemper virus infection or are due to the effect of other immunosuppressive agents (Dubey & Beattie 1988).

This is in marked contrast to neosporosis which is a primary pathogen of dogs (Dubey et al. 1988a)

The immunohistochemistry technique used in the present study (Lindsay & Dubey 1989a) proved a reliable tool for identifying *T. gondii* and *N. caninum* despite storage in paraffin blocks for up to 20 years. Positive results following a longer period of storage of tissue have been reported by other authors (Dubey et al. 1988a) who confirmed cases of neosporosis occurring in dogs in 1958.

In conclusion, this study has shown that *Neospora* infection of dogs has been present in New Zealand since 1972. The close resemblance between *T. gondii* and *N. caninum* tissue cysts prevents a definitive diagnosis using conventional histopathology, although clinical signs and the severity and distribution of lesions can be strongly indicative. A definitive diagnosis should only be made on the basis of immune techniques or ultrastructure studies. Because of the economic considerations associated with *Neospora* abortion in cattle in New Zealand (Chap. 4), and the lack of knowledge of the epizootiology of the disease further studies would be useful to determine the frequency and distribution of *N. caninum* infection in domestic animals in this country.

2.2. Cattle.

2.2.1. Introduction.

Although clinical signs have been reported in *Neospora*-infected calves, abortion is the only sign observed in infected adult cows. Aborted foetuses are usually somewhat autolysed or occasionally, mummified (Thilsted & Dubey 1989; Nietfeld et al. 1992; Thornton et al. 1991; Barr et al. 1991).

No gross findings have been reported in the aborted foetuses. However, the microscopic findings of multifocal, necrotizing and non-suppurative encephalitis are considered by

most investigators to be characteristic of *Neospora* lesions (Barr *et al.* 1991, Thornton *et al.* 1991). Although the brain is the preferential site for these lesions, the spinal cord and the heart are also equally affected although occasional fetuses also have the lung and kidneys involved (Barr *et al.* 1990). Despite the relatively easy recognition of the lesions there are few reports of the identification of *Neospora* organisms associated with the lesions (Dubey & Lindsay 1993).

Lesions of the cotyledonary placenta have also been associated with *Neospora*-infection (Barr *et al.* 1990; Thornton *et al.* 1991) but once again parasites were rarely identified in these lesions (Shivaprasad *et al.* 1989).

The following investigation was undertaken to attempt to identify *Neospora* organisms in aborted material using immunohistochemical techniques. The histological changes present in the brain and placental material were also studied.

2.2.2. Materials and Methods.

For histological examination portions of CNS from three aborted fetuses and two aborted placentas in the last trimester of gestation were obtained from Batchelar Animal Health Laboratory (BAHL), Palmerston North. The material had the presumptive previous diagnoses of *Neospora*-abortion made on the basis of the histological findings. The tissues were fixed in 10% formalin. Sections of tissue were routinely processed embedded in paraffin, sectioned, and stained with haematoxylin and eosin (H&E) and periodic acid Schiff (PAS). Immunoreactivity directed against *Neospora caninum* and *Toxoplasma gondii* was examined using the procedures previously described (see section 2.1.2). The reliability of the tests were checked with positive and negative controls for both sera each time the procedure was undertaken.

2.2.3. Results.

- Pathology.

In the brains, the characteristic histological lesions of a multifocal, necrotizing, non-suppurative encephalitis were observed. These foci were randomly scattered throughout the white matter of the brain and were more obvious in the brain stem. No lesions were found in the grey matter although in some sections it was difficult to recognize the cerebral cortex. Most of the foci were small (50-100 μ m diameter) and isolated from one another (Fig 2.11). Some of them were adjacent to capillaries. The degree of necrosis varied from small focal, swollen, eosinophilic (PAS positive) groups of axons to larger foci of necrosis often surrounded by glial cells. Cyst-like protozoa structures were seen in one brain in the H&E or PAS stained sections.

In the placentas, there was a multifocal, necrotizing, cotyledonary placentitis. Numerous foci of necrosis were present in the trophoblast epithelium of cotyledonary villi. Occasionally the trophoblast epithelium had sloughed and was surrounded by concentric laminar sheets of necrotic material giving an "onion skin" appearance (Fig 2.12; 2.13). A moderate oedema, with a few infiltrating lymphocytic inflammatory cells, was observed in the underlying chorionallantoic membrane. The intercotyledonary region showed no significant lesions.

- Immunohistochemistry.

In the sections of brain, individual and clusters of zoites were revealed by immunohistochemistry. Most of these parasites were associated with the necrotic foci. Only one thick-walled cyst-like structure was found in several sections examined from two of the cases but several cyst-like structures were observed in the third case. All zoites (Fig 2.14) and cysts reacted with the anti-*Neospora* serum. Neither the zoites nor the cyst-like structures reacted with anti-*Toxoplasma* sera.

Figure 2.11. A focus of non-suppurative inflammatory necrosis in the brain of an aborted bovine foetus. H&E x65

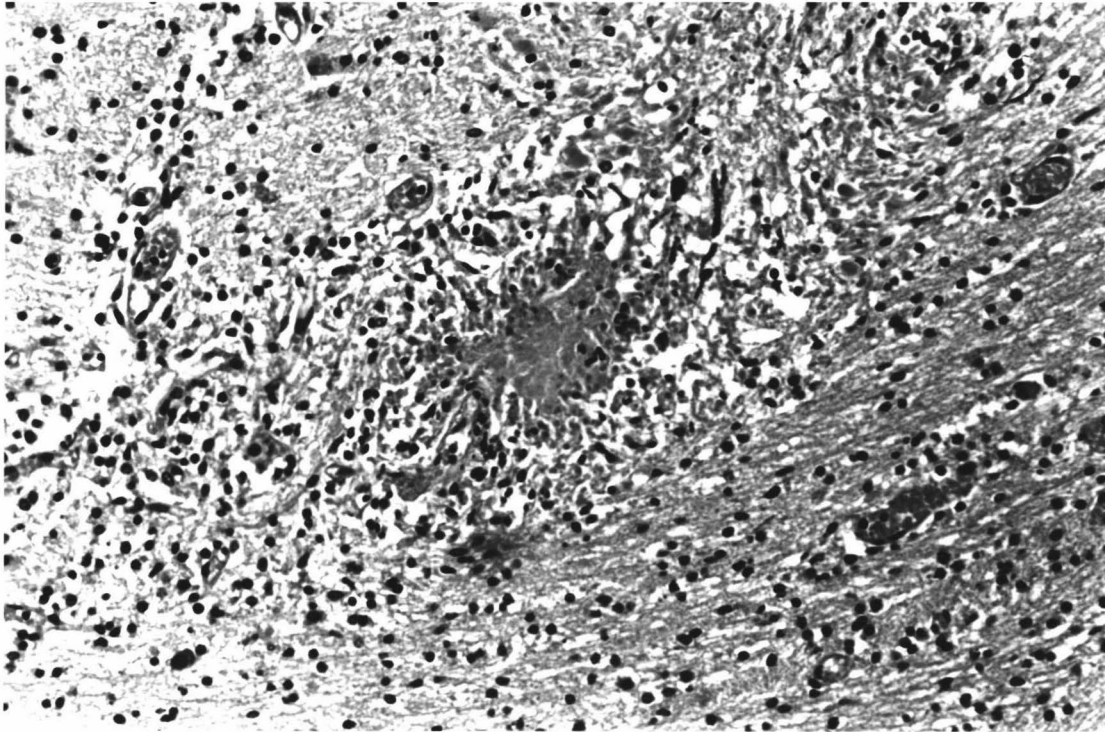


Figure 2.12. A focus of necrosis and desquamation of the trophoblast epithelium in an aborted bovine placenta infected with *Neospora*. Moderate numbers of mononuclear cells are present in the chorioallantoic membrane. H&E x68

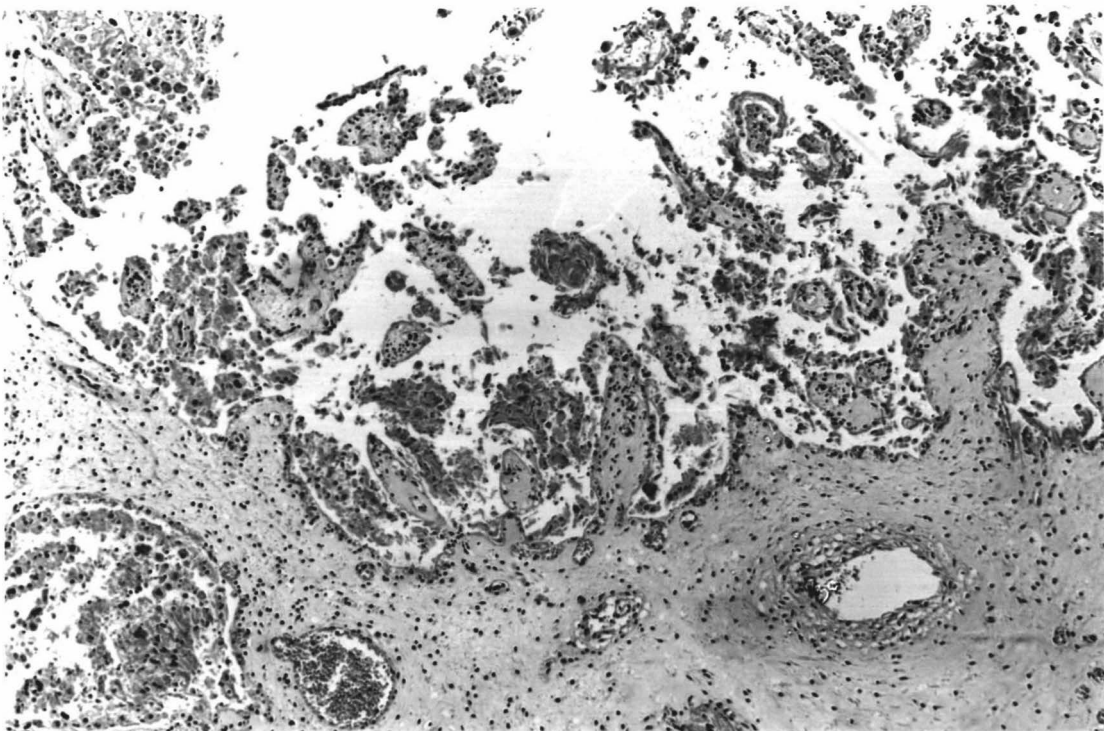


Figure 2.13. Necrosis and desquamation of the trophoblast epithelium. H&E x350

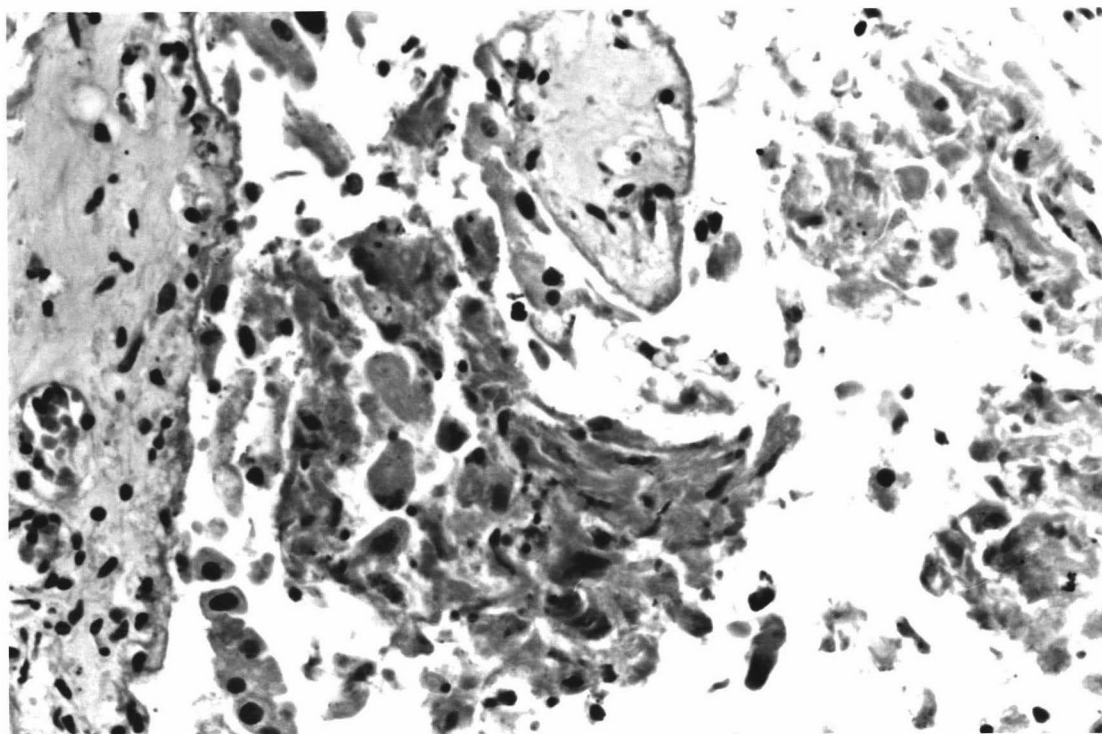
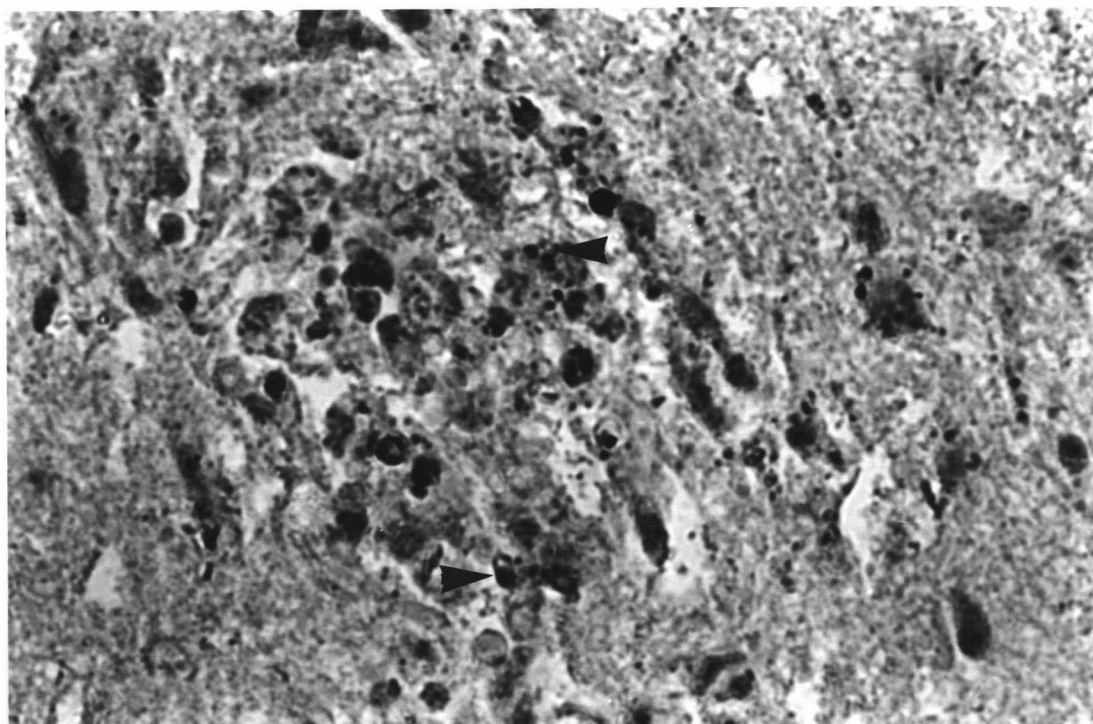


Figure 2.14. The brain of an aborted bovine foetus showing individual zoites of *Neospora* (arrows) within an inflammatory focus. ABPC x680



Although some background immunostained granular material was observed in some trophoblastic epithelial cells of the placentas, no definitive zoites or cyst-like structures reacted either with anti-*Neospora* or anti-*Toxoplasma* sera.

2.2.4. Discussion.

The multifocal, non-suppurative encephalitis observed in the present cases is typical of the characteristic lesions observed in protozoal encephalitis of bovine fetuses (Thornton *et al.* 1991, Barr *et al.* 1992, Anderson *et al.* 1991, Nietfeld *et al.* 1992). Since *Toxoplasma gondii* is not a causal agent of bovine abortion and *Sarcocystis* spp. can be ruled out because of the distinctive histological nature of the lesions (see 1.2.4 and 1.3.3), a presumptive diagnosis of *Neospora*-induced abortion can be made in bovine fetuses with these lesions.

In the cases examined the necrotic foci were more evident than the inflammation and glial reaction. This is probably related to the fact that older fetuses can develop an effective immune response (Banks 1982; Osburn *et al.* 1982) and therefore a more severe lesion than young fetuses. as reported in other studies, the lesions were more evident in the white matter of the brain with a preference for the brain stem (Barr *et al.* 1990; Anderson *et al.* 1991). The marked degree of autolysis usually observed in the softer parts of the brain (eg. the cerebrum) is thought to be responsible for this situation. However, grey matter involvement has been reported by others (McIntosh & Haines 1994; Ogino *et al.* 1992; Otolé & Jeffrey 1987) and this constitutes a histological difference from the encephalitis seen in aborted lambs caused by *Toxoplasma gondii* which produces only leukomalacia (Hartley & Kater 1963).

Parasitic structures were seen with conventional histological techniques in the brain in only one case. *Neospora* spp. zoites were detected in moderate numbers by immunohistochemical reaction in several sections in all three

cases. Previous reports have suggested that the percentage of foetuses with positive-reacting protozoa varied greatly after 6 months of gestation (Barr et al. 1991; Ogino et al. 1992).

The placental lesions resemble those previously described in naturally occurring cases of neosporosis (Thornton et al. 1991; Barr et al. 1991) and in experimentally-infected cows (Barr et al. 1994a). In the present cases, the necrosis and desquamation of the trophoblast epithelium was the most obvious lesion although a mild mononuclear infiltration was also present.

The immunohistochemical staining of the placentas did not reveal any individual or clusters of organisms or cyst-like parasitic structures. However, "dust-like" stained material could be found in occasional necrotic foci. It is possible that this was haemoglobin-like pigment which, despite the high concentration of hydrogen peroxide used (5% during 30min.), was occasionally seen in some sections. It is also possible is that this material was the remains of *Neospora* antigen. Similar antigen material has been described previously in sheep placenta stained with anti-*Toxoplasma* sera (Uggla et al. 1987). The high specificity of the ABPC test used in this study supports the latter possibility.

The present study appears to be in agreement with previous work which has shown that a presumptive diagnosis of neosporosis based on multifocal, non-suppurative encephalitis in aborted bovine foetuses is likely to accurately reflect the presence of *Neospora* spp. antigen. The presence or absence of different stages of *Neospora* organisms has been reported to be related to the immune status of the foetus and it may explain the different histological appearance seen in these cases. The immunohistochemical staining technique confirmed *Neospora* organisms in CNS tissue of the aborted foetuses which would seem to support the views of other authors who have proposed this

2.3. Attempted transmission of *Neospora* spp. to dogs.

2.3.1. Introduction.

Neospora caninum is a cyst-forming coccidial protozoa with similarities to *Toxoplasma gondii* and *Sarcocystis* spp.. Consequently the organism should have a prey - predator life cycle with a carnivore as the definitive host where the sexual phase of the parasites life cycle would occur; if so, this definitive host is still unknown. Identification of the definitive host would be of great benefit to the cattle industry as it would enable appropriate measures for prevention and control of infection in cattle to be introduced.

Since no experimental studies of transmission of *Neospora* sp. have been conducted in New Zealand, it was decided to attempt to inoculate dogs with infected bovine material in order to produce infection. The trial had the following objectives:

1. to attempt to transmit infection to and reproduce the disease in pups.
2. to attempt to isolate *Neospora* sp. from experimentally-infected pups.
3. to attempt to identify sexual stages of *Neospora* sp. in experimentally-infected pups.

2.3.2. Materials and methods.

a. Animals - Six New Zealand sheepdog puppies were obtained from the Animal Health Service Centre, Massey University. The puppies were about two weeks old and came from the same litter. At the time of the inoculation all were clinically normal as was the dam. The dam had been vaccinated against canine distemper/hepatitis and parvovirus but no other clinical history was available. The puppies were housed with their mother in a clean isolated cabinet with access to water. Three puppies (N^{os} 52, 53, 57, 58) were inoculated with infected material whereas two puppies (N^{os} 54, 56) were used as uninfected controls. Faeces

were collected from all puppies at 3 to 4 weeks of age. At the end of the experiment (4 weeks PI), all the puppies were killed using pentobarbitone and necropsied immediately. The trial was undertaken after the approval of the Massey University Animal Ethics Committee.

b. Inoculum - Bovine foetal brain tissue from a histologically confirmed case of *Neospora* sp. abortion was obtained from Batchelar Animal Health Laboratory (BAHL) in Palmerston North. The foetal brain came from an aborted fetus from a dairy herd with a previous history of *Neospora* abortion. Half the brain was stored at 4 C until the diagnosis was confirmed by immunohistochemistry (Lindsay and Dubey 1989). It was then processed using the technique described by Dubey et al. (1988). Initially it was disrupted in saline (0.85% NaCl) by use of a pestle and mortar, then filtered through a 3-400µm metal sieve, and centrifuged at 400G for 10 minutes. The supernatant was discarded and the sediment was suspended in approximately 10 ml of sterile saline solution containing 1,000 IU of penicillin and 100 µg of streptomycin/ml. The same homogenate was prepared for oral and intraperitoneal routes of inoculation.

c. Inoculation - Puppies 52 and 53 were given 1.5ml of the inoculum orally. Puppies 57 and 58 were intraperitoneally inoculated with 1.0ml of inoculum.

d. Oocysts in faeces - The faeces collected were examined for oocysts and other parasite stages which might be associated with transmission. The method used was a flotation technique in which approximately 5g of faeces were put in a small container, broken down in water and filtered through a wire mesh screen with an aperture of 0.15mm. The debris left on the screen was discarded and the filtered faeces were suspended in fully saturated NaCl (SG 1.204) solution until a convex meniscus was formed at the top of the tube. The suspension was then covered with a cover glass and allowed to stand for approximately 20 min. After this time the cover glass (to which any oocysts would

adhere) was removed from the tube, mounted on an microscope slide and examined at 400x.

2.3.3. Results.

All the puppies remained clinically normal throughout the experimental period.

At 4 weeks PI, when the puppies were necropsied, no gross pathological findings were observed. Samples from the CNS tissue (brain and spinal cord), liver, kidney, lung, small and large intestines, stomach, pancreas, eyes, skeletal muscle (both hind and forelegs), myocardium and tongue were fixed in 10% formol saline for histological examination. None of these tissues showed histopathological lesions when examined microscopically and no protozoan organisms or cysts could be identified in any tissue section.

Faecal examinations of the experimentally infected animals did not reveal the presence of any apicomplexan protozoan organisms at any stage.

No evidence of protozoal infection was detected in the two control animals.

2.3.4. Discussion.

The experiment reported here was unsuccessful in transmitting *Neospora* spp. infection to young puppies using infected brain homogenate from an aborted calf. The lack of infectivity of the homogenate may have been due to a number of possibilities.

In dogs infected naturally with *N. caninum* (of canine origin) the most severe disease has been described in young animals (Dubey *et al.* 1992a, Mayhew *et al.* 1991, Hay *et al.* 1990). In all these cases however, the disease was acquired

congenitally, whereas in the present experiment the puppies were inoculated 2 weeks after birth. The pathogenesis of infection and the role maternal immunity has in these circumstance is not known. A better knowledge of the dam's immunological status would have been useful in this regard.

Since *Neospora* spp. are cyst-forming apicomplexans, it is likely that they share with this group of related protozoa the characteristic of bradyzoites in tissue cysts rather than tachyzoites being the main stage involved in transmission from the herbivore to the carnivore host (Dubey 1977;1993). It was therefore assumed that the calf brain containing cysts was the best choice of infected material. Emphasis was put on selecting a brain with a relatively large number of parasites as well as one which was reasonably fresh. Previous work by Barr et al. (1990, 1991) has shown that autolysis was a limiting condition for the isolation of *Neospora* from aborted calves. The calf brain was maintained at 4 C for a period of 12 days before use in order to confirm infection and obtain recently born puppies for inoculation. This prolonged period of storage could have been responsible for the failure to infect. However, a longer period of storage preceded successful isolation of organisms in tissue culture (Conrad et al. 1993). The routes of inoculation employed here have also been used successfully by other workers with *N. caninum* (Lindsay & Dubey 1989c, 1990b).

The present work, although a small-scale experiment, failed to produce any evidence to incriminate dogs in the transmission of *Neospora* spp. It is known that cattle experimentally inoculated with *N. caninum* (of canine origin) can be induced to abort (Dubey et al. 1992b) but whether or not the natural bovine infection is caused by *N. caninum* is not certain at the time of writing. Therefore until more evidence is available it is important that research on the canine organism should be segregated from work on the bovine organism (Smith 1993).

CHAPTER 3.
A SEROLOGICAL STUDY OF A DAIRY HERD WITH A RECENT HISTORY OF
NEOSPORA ABORTION.

3.1. Introduction.

Until recently, the diagnosis of *Neospora* infection has been based on the identification of characteristic lesions and/or tissue cysts in haematoxylin and eosin (HE) stained histopathologic sections, combined with immunohistochemical tests to detect tachyzoites and confirm their identity by reactivity with *Neospora caninum* antisera (Anderson *et al.* 1991; Barr *et al.* 1991).

Using these techniques *Neospora* organisms have been associated with neonatal paresis, encephalomyelitis and abortion in cattle (Dubey & Lindsay 1993). *Neospora* associated abortion has now been reported from many countries including New Zealand (Thornton *et al.* 1991; Dubey 1992a).

In all these reports, the diagnosis of neosporosis was made on the basis of the examinations of aborted material as it was not possible at that time, to test for evidence of *Neospora* infection in live cattle.

Only in the last two years has the development of an indirect fluorescent antibody (IFA) test, allowed a new approach to the diagnosis of *Neospora* infection. Initially the test was successfully employed to identify *N. caninum* infections in dogs (Dubey *et al.* 1988b; Trees *et al.* 1993), but later it was demonstrated to have potential application for the diagnosis of *Neospora* infections in cattle (Trees *et al.* 1994; Conrad *et al.* 1993b; Thornton *et al.* 1994).

The first IFA test was developed by Dubey *et al.* (1988b) using culture-derived tachyzoites of *N. caninum* (NC-1) isolated from dogs as antigen. In this study, *N. caninum* IFA titres were

found in naturally and experimentally-infected dogs and in experimentally-infected mice. A similar procedure using the same *Neospora* strain (NC-1) was also used in a second study (Trees *et al.* 1993) on a population of urban dogs in England.

Knowledge of the antigenic similarity between *N. caninum* and other *Neospora* spp. and the availability of this serologic test soon motivated researchers to use the IFA test for the diagnosis of neosporosis in cattle. Unfortunately however, these earliest attempts were not successful as most commercial batches of foetal calf sera (used in the cell culture of *Neospora caninum*) already had antibodies to *Neospora* sp. (Dubey & Lindsay 1993).

More recently, encouraging results were obtained by Trees *et al.* (1994) using the NC-1 isolate of *N. caninum*, cultured in Vero cells and grown in a medium without serum supplementation. About the same time, Conrad *et al.* (1993a) first isolated the parasite (BPA1) from an aborted bovine foetus and used this strain as the antigen in a IFA test for identifying *Neospora*-infected cattle (Conrad *et al.* 1993b). This initial evaluation of the test was successful in detecting antibodies in both naturally and experimentally-infected cattle, although because of cross-reactivity with other closely related protozoa there was some trouble in identifying animals that were unquestionably free of *Neospora*.

Using the test developed by Conrad *et al.* (1993), interesting preliminary data were obtained from two dairy farms in California (USA) (Pare *et al.* 1994). The sera were tested at a cut off titre of 1:640 and a prevalence of approximately 30% seropositive animals were found in precolostral calves and adult cattle allowing speculation that the herd infection may be maintained, after initial infection, through congenital transmission.

Because there is a current worldwide lack of knowledge of the seroprevalence of *Neospora* spp. it was decided to undertake a study of a dairy farm which had recently experienced an outbreak of *Neospora* abortion. The purpose of this work was to determine the *Neospora* spp. seroprevalence in cattle of different age groups.

3.2. Materials and Methods.

- Farm history.

The dairy farm used in this study had recently experienced a storm of abortions confirmed by the BAHL as *Neospora*-induced. It was located in the Taranaki area of the North Island of New Zealand and was of "seasonal" type with a calving season in July, August and September. The cows were Friesian and were fed on pasture throughout the year, receiving some supplementary feed (hay) when there was a shortage of grass. Artificial insemination was used for the whole herd and replacement heifers were reared on the same farm, but were grazed off the farm for approximately one year. The herd was "closed", ie. no animals were introduced from other farms. Three dogs, two cats, and a few horses and hens were also present on the farm.

The herd had a population, at July 1994, of 267 animals comprising 34 calves, 33 weaner heifers, 60 young cows (born in 1990 and 1991) and 150 older cows. Twenty one abortions were notified as follows: 18 between 20/4/94-25/5/94, 1 on 10/6/94 and 2 at an unrecorded time. Sera were obtained from all the calves, 32 weaner heifers, 59 young cows and 101 randomly selected older cows.

Serum from each animal was stored at -20 C until tested. In an attempt to overcome difficulties with non-specific reactions some sera were heat inactivated at 56 C for 30 min. For the detection of antibodies to *N. caninum*, the sera were diluted in phosphate buffered saline, pH 7.2, at 1:400 titre.

- Indirect fluorescent antibody (IFA) test.

Twenty five slides containing *N. caninum* infected Vero cell cultures spotted onto the surface of teflon masked slides and an anti-cow IgG1-IgG2 (fluorescein isothiocyanate conjugate) were obtained from Veterinary Medical Research and Development, Inc. (VMRD), Pullman, WA USA.

Slides with 20 μ l of diluted serum added per well were first incubated for 30 min in a humidity chamber at 37 C. and then were washed and soaked for 10 min in FA rinse buffer, pH 9.0 (VMRD, Inc.). They were then incubated in fluorescein isothiocyanate-labelled anti-cow IgG as in the first incubation, washed and soaked again, then mounted with mounting fluid (glycerol/FA rinse buffer 50/50), and examined under an epifluorescent microscope. Diffuse or peripheral staining of entire organisms was considered positive and apical staining was considered nonspecific cross-reaction. Positive and negative controls were used with each set of slides processed together.

- Data analysis.

Paradox was used as a database. A Chi-square procedure was performed with the SAS program. The first Chi-square analysis involved all the variables together and then a Chi-square test for each pair for variables was carried out. A Drawperfect Presentation program was used for the graphics.

Estimation of sample size required to yield statistically valid data was calculated in STATCALC program (Epi-info 6.00). Using a confidence level of 95% and an expected frequency of 38% (based on Pare et al. 1994), the required sizes of each group were: 32 calves, 30 weaner heifers, 44 young cows and 109 adult cows. As noted earlier, 34 calves, 32 weaner heifers, 59 young cows and 101 older cows were tested.

3.3. Results.

The results obtained are shown in Figure 3.15. The proportion of seropositive animals for each group were: 32% (11/34) of calves, 3% (1/32) of weaner heifers, 31% (18/59) of young cows and 27% (27/101) of adult cows. The mean (excluding the weaner heifers) was 29% (56/194) and the 95% confidence limits were 23% to 35%. The heat inactivation of sera had no effect on the results.

A significant difference in the number of seropositive animals was found when all the groups were considered together ($p < 0.01$).

In order to test the significance of the differences between age-groups a Chi-square analysis was performed for each age group versus other age groups. The "weaner heifer" group differed significantly ($p < 0.01$) from each of the other groups. However, the "calves", "young cows", and "adult cows" groups showed did not differ significantly.

The diffuse peripheral staining considered positive (Fig 3.16). This was different to the apical fluorescence pattern (Fig 3.17) which was seen in 10 (29%) calves, 9 (28%) weaner heifers, 15 (25%) young cows, and 14 (14%) adult cows (mean= 25%, and 95% confidence limits= 19% to 31%).

All the 21 aborting cows, apart from cows N^{os} 102 and 212, were seropositive at a 1:400 titre. In order to find the maximum titres of the aborting cows, different serum dilutions were tested (table 3.1). Cows N^{os} 102 and 212 (both negative) were reported as cows which had aborted earlier than April and were bled with the main group (two months after the abortion storm). Cows N^{os} 34, 64, 42, 174, 86, 109, 111, 127, 141, and 187 were bled at the time of abortion, and cows N^{os} 1, 14, 45, 89 and 94 were bled 2 months after the abortion occurred.

Figure 3.15.

Percentage of cattle positive to the Neospora IFA test in different age groups.

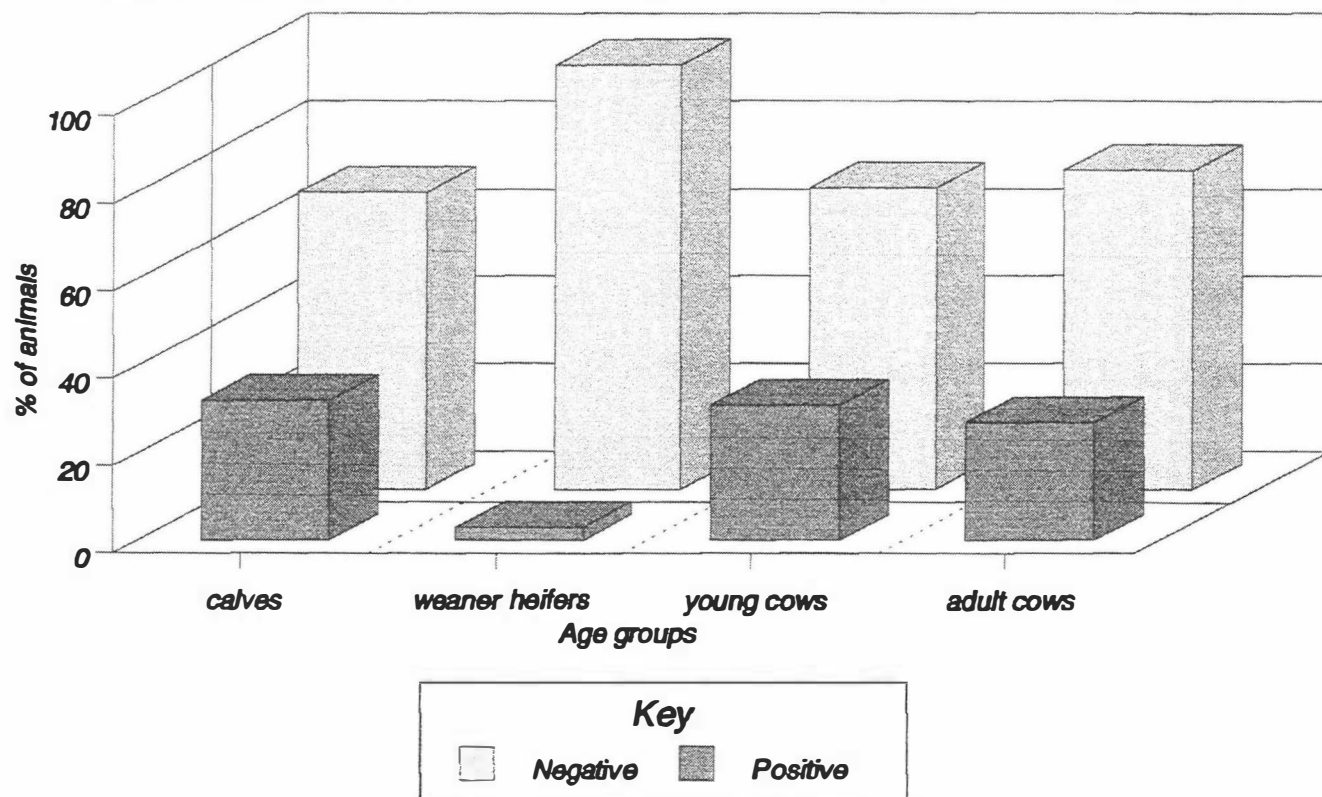


Figure 3.16. Tachyzoites of *Neospora* in a positive indirect fluorescent antibody test. Note the brightness of the whole parasite. x400

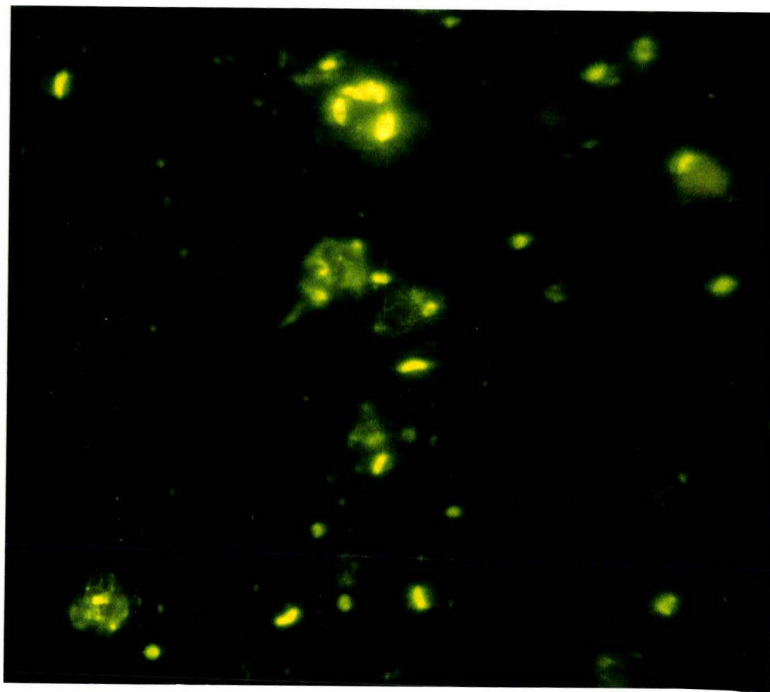


Figure 3.17. Tachyzoites of *Neospora* in a negative sample of indirect fluorescent antibody test. Note the apical brightness at the anterior end of the parasite. x800




TABLE 3.1: *NEOSPORA* IFA TEST RESULTS ON SERA FROM ABORTING COWS.

Cow N°	Serum dilutions				
	1:400	1:1600	1:6400	1:12800	1:25600
Cows bled at the time of abortion.					
34	+	+	+	+	-
42	+	+	+	+	*
64	+	+	+	-	*
86	+	+	+	+	*
109	+	+	+	+	*
111	+	+	+	+	*
127	+	+	+	+	*
141	+	+	+	+	*
174	+	+	+	+	+
187	+	+	+	+	*
Cows bled two months after the abortion.					
1	+	-	-	-	-
14	+	+	*	-	-
45	+	+	+	-	*
89	+	+	+	-	*
94	+	+	+	-	*

* : not tested.

The results show that 9/10 cows bled at the time of abortion had titres > 1:12800 whereas 0/5 cows bled 2 months after aborting were positive at this dilution.

3.4. Discussion.

The weaner heifers were the only group of cattle on the farm with a low prevalence of *N. caninum* antibodies (1/32). The one positive animal in this group may have been due to an odd non-specific reaction or a low background level of infection on the property where they were kept. Since the weaner heifers were grazed off the farm at the time the outbreak occurred, the most likely explanation for the difference was that they avoided the infection. This observation provides strong, if indirect,

evidence that the infection is transmitted by means of an infectious agent present in the environment.

The other groups (calves, young cows and adult cows) all had a similar prevalence of approximately 30% suggesting that the infective agent was widely available at the time. These results are similar to the preliminary data published by Pare *et al.* (1994) in which the herd had a seropositivity of approximately 34% with no significant increase in the rate of infection with age. Higher values (about 50% prevalence) were reported in New Zealand by Thornton *et al.* (1994). In the latter study, similar prevalences were reported in adult cattle and heifers (though not statistically tested) and the laboratory analysis was done in Canada using a "cutoff" dilution of 1:200 in sera from animals bled 5 months after the outbreak. Direct comparison of these results with those in the present study is therefore not possible.

The recommendation for the use of the test (VMRD, Inc. Laboratory) was that bovine sera should be screened at 1:200 for IgG.. Our decision to use a cutoff titre of 1:400 was made on the basis of the limited published data available. Trees *et al.* (1994), in an attempt to evaluate the significance of bovine *Neospora* abortion in Britain, considered a positive reaction at a dilution of 1:1280 as an indication of *Neospora* abortion. This approach included most of the infected cattle, but by no means all, since a high proportion of infected dams (22%) have been reported to have titres between 1:320-1:640 (Conrad *et al.* 1993b). Moreover, it is known that *Neospora* antibody levels change with time (Conrad *et al.* 1993b) although it is not yet certain how much they vary. Current data suggest titres increase up to a peak of the time of abortion and subsequently decrease within the first 5 months post-abortion (Conrad *et al.* 1993b) showing a diversity of values at each of these extreme points. Bearing this in mind it was decided to screen the sera at a conservative cutoff point of 1:400.

Pare *et al.* (1994) speculated that *Neospora* infection once established, may be maintained thereafter through congenital transmission. Unfortunately, we could not validate this hypothesis because the calves in the herd studied were approximately 5-7 months old at the time of bleeding. For this reason it seems that it is more likely that the high titres obtained in calves were due to recently acquired infection rather than congenital transmission. The possibility that these are maternal antibodies is not likely since the limited evidence available suggests that *Neospora* antibodies in some animals can drop to $\leq 1:160$ over a 1-5 month period (Conrad *et al.* 1993b).

The additional data presented in Table 1, show titres of aborting cows at two different time periods. The two cows (102 and 212) which were serologically negative may have been empty as a result of infertility problems other than *Neospora*-infection since no foetus was available for diagnosis. The titre variation between the rest of the aborted cows is most likely due to the different times at which the infection was contracted, although titres ranging from 1:320 to 1:5120 have been reported in sera taken at the time of abortion (Conrad *et al.* 1993b).

In the present study most of the aborted cows showed a maximum titre of 1:12800 which was twice the maximum titre for aborting cows reported by others (Conrad *et al.* 1993b; Trees *et al.* 1994); similar values were only found in experimentally-inoculated heifers and in naturally congenitally-infected calves (Conrad *et al.* 1993b).

Data obtained from the farmer revealed that 86% (18/21) of the abortions occurred over a short period of time. This "cluster" occurrence of abortions supports the view that the herd became infected over a limited time interval and suggests a common source of infection (Thornton *et al.* 1991; 1994). The possibility that the animals had access to hay contaminated with faeces of a carnivore, as occurs in *Toxoplasma* infection sheep (Underwood & Rook 1992), was unlikely in this case since no hay was fed prior to the outbreak.

The results also showed that a large proportion of the herd (approximately 25 %) had sera which only reacted with the apical end of the parasite. This reactivity may be due to antigens in the apical complex structure of *Neospora* which are shared with other closely related apicomplexans (Conrad et al. 1993b). *Sarcocystis* spp. infections appear to be common in New Zealand cattle (Böttner et al. 1986; Mitchell 1988) and other related protozoa such as *T. gondii* (see section 1.3), *Hammondia* spp. and *Besnoitia* spp. have been also reported in New Zealand although not in cattle (McKenna 1978). These parasites and others may therefore be responsible for the cross-reactivity.

Although it was not a major problem, some difficulty arose in the interpretation of fluorescence in some sera. Differentiation of apical fluorescence from whole parasite fluorescence was sometimes difficult because both fluorescence patterns, were present in the same sample but with different degrees of brightness. The results were interpreted on the basis that only marked whole parasite fluorescence was considered positive. A possible explanation for the presence of both types of fluorescence may be that both *Neospora* and a cross-reacting infection were present. Another possibility may be that *N. caninum*, rather than bovine derived *Neospora* (Conrad et al. 1994), was used as antigen, although Trees et al. (1994) reported no interpretation problems using the same strain of *N. caninum* (NC-1). The interpretation problem was present in both heat inactivated and non-inactivated groups of sera.

With the limited data obtained in the present study it can be concluded that the *Neospora* IFA test is a useful adjunct in the diagnosis and study of neosporosis in cattle. The different degrees of brightness observed between a weakly positive and non-specific reaction may rely to some extent, on personal interpretation which would make between laboratory comparisons difficult. Despite this consideration, the present results demonstrate that *Neospora* infection on this particular dairy farm was high (approximately 30%) and there was no statistical

differences between the age groups except for the weaner heifers which were off the farm at the time of the infection. Thus it seems likely that infection in the present farm occurred at one time and all the exposed animals were equally susceptible.

This serological study undertaken in a New Zealand dairy herd has provided some preliminary data related to the epidemiology of *Neospora* spp. infection. Future research involving more extensive studies should now be undertaken in order to obtain an accurate estimate of the prevalence of the infection and the likely incidence of disease. In particular, studies of infected dairy herds with different management systems are necessary in order to clarify the role of grazing replacement heifers off the farm, the time at which infection is initially acquired as well as the source of infection. Answers to these questions are of vital importance before any advice can be given on preventing or controlling the disease.

CHAPTER 4.
AN EPIDEMIOLOGICAL STUDY OF ABORTION DUE TO NEOSPORA SPP. IN
DAIRY HERDS OF THE NORTH ISLAND.

4.1. Introduction.

Since the first report of neosporosis in cattle, most scientific literature has been concerned with the pathological aspects of the disease. Very few reports (Nietfeld *et al.* 1992, Anderson *et al.* 1991, Thornton *et al.* 1991) have attempted to characterize the epidemiologic features of *Neospora* abortion in cattle. Lack of knowledge of the life cycle of the parasite and the relatively recent history of the disease have made epidemiologic studies of this disease unattractive.

However, a knowledge of the epidemiological features of *Neospora* abortion would be useful in providing information for controlling the disease, diminishing the losses due to abortion and possibly provide some clues as to the mode of transmission. In order to do this, investigations of the disease prevalence, source of infection and/or risk factors associated with the disease are needed.

The purpose of the present study was to attempt to identify epidemiological factors associated with *Neospora* abortion on dairy farms and compare these with data obtained from dairy farms experiencing abortion due to other causes. The study involved a mailed questionnaire survey of dairy farmers in North Island of New Zealand who had experienced abortion in the 1992 season.

4.2. Material and Methods.

Study design.

The study design employed was a case-control study using a matched and a random control for each case studied.

The sample population was composed of dairy farms which had experienced abortions in the 1991-1992 period and submitted aborted material to either the Batchelar Animal Health Laboratory, Palmerston North or the Ruakura Animal Health Laboratory, Hamilton. These two laboratories receive samples from the three largest dairy areas of the North Island (Taranaki, Manawatu and Waikato). The fourth important dairy area, Northland, submits samples to the Glynfield Animal Health Laboratory, Auckland, and was not included.

The *Neospora* abortion group ("cases") was compiled from all the farms which suffered *Neospora* abortions in the 1991-1992 period. Diagnosis of a *Neospora* abortion was made on the basis of histopathological lesions observed in the brain and/or heart and/or skeletal muscles of aborted calves.

The control groups were compiled by selecting farms that experienced abortions due to causes other than *Neospora* during the same period. The causes of abortion in these groups were variable (eg: leptospirosis, BVD, Not known, etc) and diagnosis was made on the basis of histological, serological and microbiological examination. The brain was examined in all the aborted fetuses in the control groups and no lesions suspicious of *Neospora*-like infection were observed. From these farms a group of geographically matched controls was compiled ("matched" group). They were chosen by their close proximity to the farms experiencing *Neospora* abortions. After plotting the location of farms experiencing abortion on a map of the local area, the farm with the nearest possible location to a farm experiencing *Neospora* abortions was chosen. A second "random" control group was also compiled. It was composed of individual farms also with abortions due to causes other than *Neospora*. They were selected by a Simple Random Sampling method (Dawson-Saunders & Trapp 1990) using a table of random numbers.

The number of farms sampled in each group is shown in Table 4.1.

TABLE N° 4.1: NUMBER OF DAIRY FARMS EXPERIENCING ABORTION IN THE CASE-CONTROLLED STUDY

Laboratories	Cases *	Controls	
		Matched **	Random
BAHL	21	21	21
RAHL	57	57	57

BAHL: Batchelar Animal Health Laboratory

RAHL: Ruakura Animal Health Laboratory

* : farms experiencing abortions diagnosed as *Neospora*.

** : farms matched on geographic location.

Questionnaire.

A questionnaire form was designed for dairy farmers, (Appendix). The questions included: characteristics and general information about the farm, descriptive aspects of the herd and any information likely to be relevant to the transmission of the disease. Some of the questions were historical and referred to previous years (1989-1992).

The questionnaire forms were mailed to the farmers via their local veterinary practitioners during May 1993. A letter explaining the objectives of the study and a franked return envelope were included with each questionnaire.

Data.

Paradox and Dbase III programmes were used to develop data bases. The statistical analysis was made using Epi-Info 6.00. Each variable was analysed in a 2 by 2 table ("cases" vs "random") with the "tables" command in ANALYSIS programme. The procedure provided "odds ratio", "chi-square" and "confidence interval" values for each variable analysed. For the "matched"

control, a "match" command with the same calculation was used. The "power" of the test and the "sample size" were estimated by STATCALC calculations. The graphs were made using the WP Presentation programme.

4.3. Results.

Between 1st January and 31st December 1992, 147 cases of bovine abortion were submitted at BAHL for diagnosis. Of these 21 (14%) showed lesions characteristic of *Neospora* infection. During same period RAHL recorded 768 abortions with 122 (15%) of the *Neospora*-type. *Neospora* was the most frequently diagnosed cause of abortion at both BAHL and RAHL laboratories.

The location of all 21 cases of *Neospora* abortion from BAHL was identified and placed on the maps of lower North Island. However, the location of only 57 cases from RAHL could be accurately identified and mapped.

A total of 234 questionnaires were mailed and 105 (44%) replies obtained which were analysable. These consisted of 35 *Neospora* "cases", 46 matched controls and 24 random controls. Only 17 cases were able to be matched with their respective controls.

The data obtained showed that all but one of the farms experiencing *Neospora* abortions in the study were "seasonal farms" with a concentrated mating season planned to obtain peak milk production in late-winter/early-spring of the next season. The mean herd size was 239 animals with a range of 115 to 440 animals.

After reading the replies, it was decided that only data for the 1992 year would be considered. Questions referring to 1989, 1990 and 1991 were ignored because of incompleteness and inconsistencies in the data. A further 12 *Neospora* "cases" questionnaires were also excluded mainly because of the

inconsistency between the laboratory diagnosis and the data reported by the farmer.

The numbers of abortions per farm, in the *Neospora* "cases" group, varied greatly. The mean was 19 fetuses aborted per farm with a range of 1 to 110. Table 4.2 shows the distribution of abortion rates for 23 farms experiencing *Neospora* abortions.

TABLE 4.2. THE DISTRIBUTION OF ABORTION RATES FOR 23 FARMS EXPERIENCING *NEOSPORA* ABORTIONS.

Percent of abortion	Number of Farms
< 3 %	5
3 % - 10 %	14
> 10 %	4

Mean= 7.4 %; range= 0.6 % - 31,4 %.

Although abortions occurred throughout the January to August period, the majority occurred in March, April and May (Fig 4.18).

The aborted fetuses ranged in gestational age from 2-8 months with a mean age of 6 months. More than 70 % of abortions were between 5 - 7 months of gestational age. The distribution of the age of the aborted fetuses from *Neospora* infected farms is presented in Figure 4.19.

When the animals aborting on *Neospora*-infected farms were categorized as young cows (first calving) and adult cows, the data obtained showed a significant difference between the two age groups with a considerably higher percentage of abortion in the young cows (Table 4.3). Since the total number of first calving cows in each herd was not known, this analysis was made by using the assumption that 20 % of the herd were heifers. This is the usual ratio of replacements in North Island dairy herds (Wilson pers. comm.).

Figure 4.18.

Abortions per month on Neospora infected farms vs. non-infected farms.

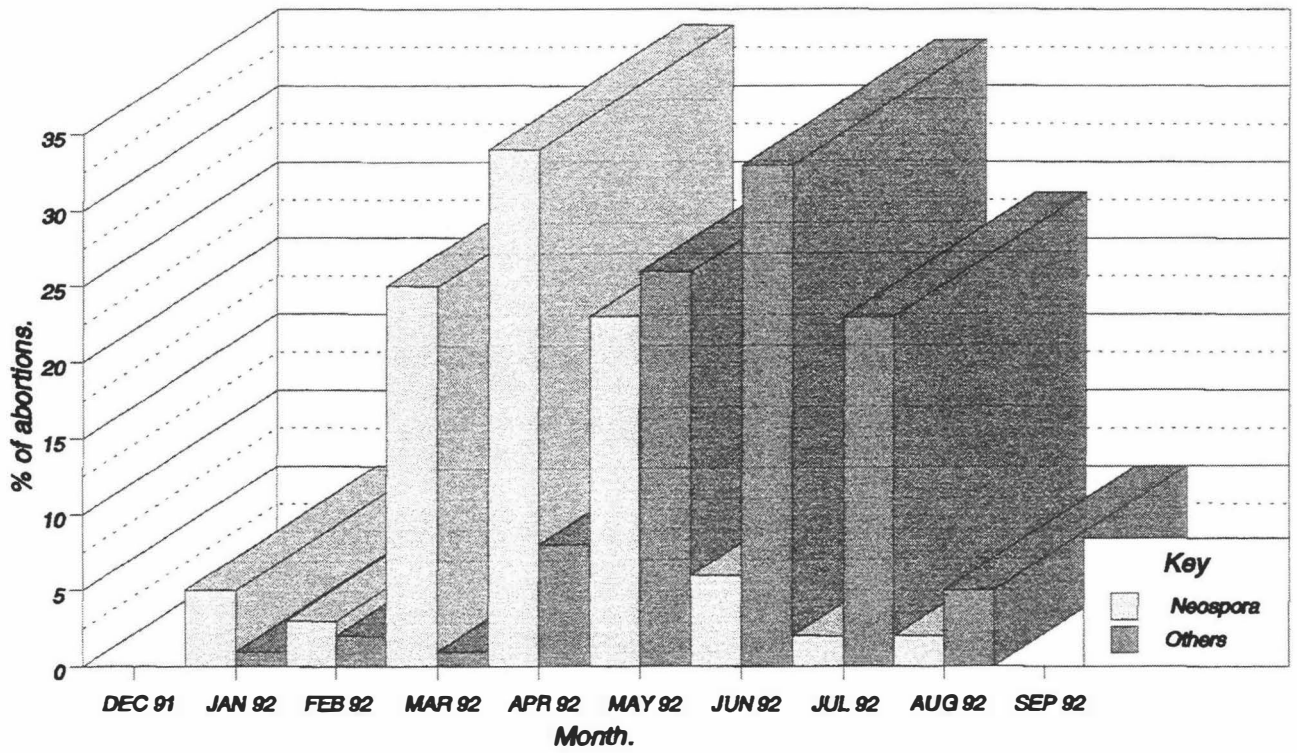


Fig 4.19.

Mean age of aborted foetuses from Neospora infected farms.

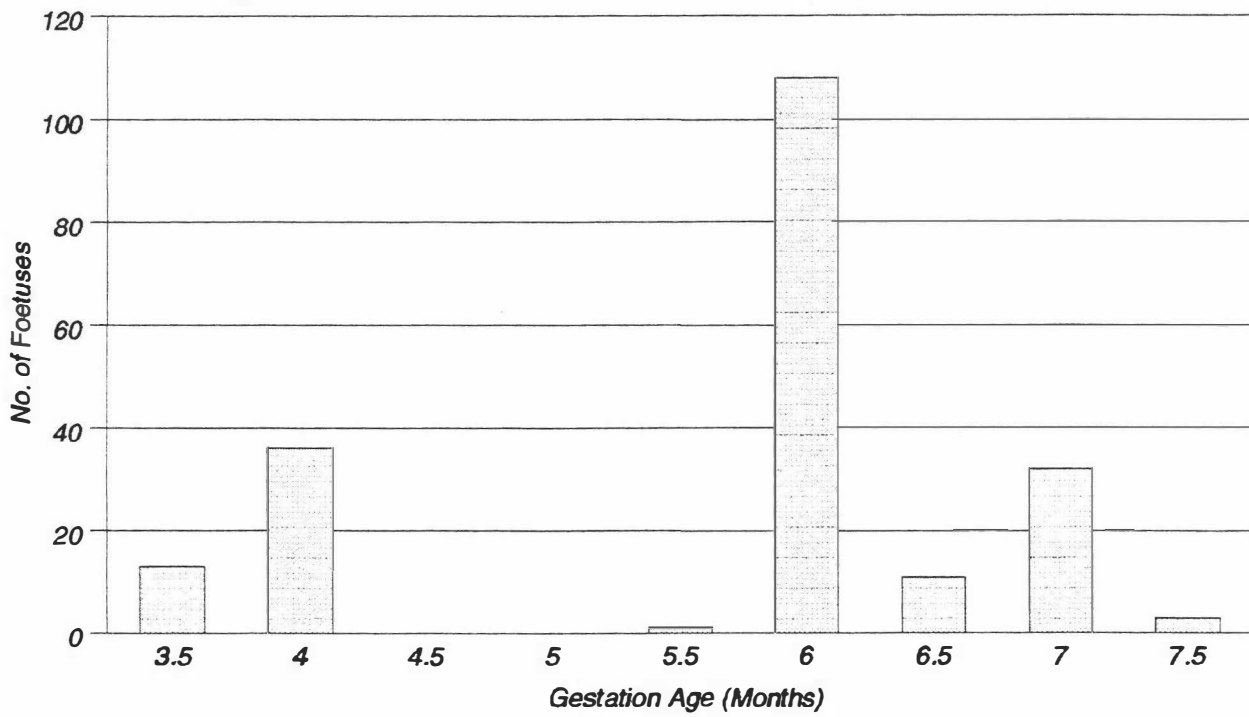


TABLE 4.3: ABORTIONS IN HEIFERS AND ADULT COWS FROM
NEOSPORA INFECTED FARMS.

	Heifers	Adult cows
Aborting	153 (14%)	282 (6%)
Not aborting	939 (86%)	4088 (93%)
Total	1092 (100%)	4370 (100%)

Chi-square= 68.09; $p < 0.01$

One farmer, who suffered a storm of abortions (37 aborted cows in a total of 236), reported that most of the fetuses were mummified and none of the aborted cows were able to produce milk.

Risk factors.

The 10 potential risk factors studied are listed in Table 4.4 and 4.5. None of these risk factors were statistically significantly associated with *Neospora* abortion cases. Tables 4.4 and 4.5 show the Odds Ratios (O.R.) and the 95% Confidence Intervals (C.I.) of these variables. The O.R. measures the relative likelihood that a farm experiencing *Neospora* abortion would be positive for this factor, compared with a standard likelihood of 1.0 for a farm with no *Neospora* abortions. In interpreting the O.R.: the hypothetical situation for the variable "dogs" (presence in dogs in the farm) in Table 4.4 would be: A *Neospora* abortion farm is 6.05 times more likely to have dogs on the farm than a farm with no *Neospora* abortion. However, since C.I. includes 1, one can not be 95% confident that the relative risk is not 1. Parallel analysis performed for some of the variables revealed **power** values of approximately 15 %.

TABLE 4.4. ODDS RATIOS OF DICHOTOMOUS RISK FACTORS (YES/NO) IN *NEOSPORA* CASES VERSUS RANDOM CONTROL ANALYSIS.

Risk factor	Odds ratio *	95% Confidence Interval
Heifers "bought in"	1,56	0.35 - 7.46
Heifers reared	2.09	0.10 - 128.6
Cows purchased	0.70	0.18 - 2.64
Heifers "grazed off"	1.40	0.39 - 5.09
Dogs on farm	6.05	0.58 - 298.4
Cats on farm	0.71	0.09 - 4.85
Stoat/ferrets	0.56	0.13 - 2.25
Feral cats	2.14	0.54 - 8.96
Other species on farm	1.18	0.33 - 4.25
<i>Neospora</i> previous year	4.60	0.40 - 236.1

*:none of them were significant.

TABLE 4.5. ODDS RATIOS OF DICHOTOMOUS RISK FACTORS (YES/NO) IN *NEOSPORA* CASES VERSUS MATCHED CONTROL ANALYSIS

Risk factor	Odds ratio *	95% Confidence Interval
Heifers "bought in"	3.50	0.67 - 34.53
Heifers reared	0.00	-- - --
Cows purchased	0.80	0.16 - 3.72
Heifers "grazed off"	4.00	0.80 - 38.67
Dogs on farm	2.00	0.10 - 117.9
Cats on farm	1.67	0.32 - 10.73
Stoat/ferrets	0.67	0.06 - 5.82
Feral cats	0.67	0.06 - 5.82
Other species on farm	0.69	0.20 - 3.28
<i>Neospora</i> previous year	0.00	-- - --

* none of them were significant.

4.4. Discussion.

The identity of the protozoa responsible for the abortions could not be confirmed in every case. However, since *Toxoplasma gondi* is not implicated as a cause of bovine abortion (Dubey

1986) and *Sarcocystis* sp. can be ruled out on the basis of its distinctive histopathologic features (Dubey & Bergeron 1982; Anderson *et al.* 1991; Barr *et al.* 1990; 1991), *Neospora*-infection is the most likely cause of abortion in these cases.

The laboratory data confirmed that *Neospora* type protozoa are responsible for at least 14-15% of the bovine abortions submitted to BAHL and RAHL during 1991-1992. Data previously reported by Thornton *et al.* (1991), indicated that protozoal lesions were seen in the brain of 28% of 320 aborted fetuses over the 4 year period (1987-1990).

Neospora abortion was the most commonly diagnosed cause of bovine abortion at both BAHL and RAHL in 1992. This is similar to the findings of Thornton *et al.* (1991) in their study of the lower area of the North Island. In some overseas regions such as California (U.S.A.), where the dairy industry is economically important and brucellosis has been controlled, neosporosis is also the most commonly identified cause of abortion (Anderson *et al.* 1991; Barr *et al.* 1991).

Batchelar and Ruakura Animal Health Laboratories are diagnostic laboratories for all but one of the dairying areas of the North Island of New Zealand. Since there was no difference in percent of *Neospora* abortions submitted to both laboratories, it could be inferred that the frequency of diagnosis of *Neospora* abortions throughout the North Island was likely to be close to 15% in the 1992 period.

The questionnaire data showed that although some farms can experience only a few abortions due to *Neospora* infection (Table 4.2), most have outbreaks involving several animals. It was also evident, (Fig. 4.18) that although *Neospora* abortions can be observed at any time during pregnancy, there was a peak of abortions reported during March, April and May. Estimation of the gestation age of the aborted fetuses revealed that more than 70% of the abortions were at 5-7 months gestation. These results are

in agreement with previous findings both in New Zealand (Thornton 1991) and overseas (Anderson *et al.* 1991; Barr *et al.* 1990, 1991; Thilsted *et al.* 1991; Nietfeld *et al.* 1992).

Abortion rates between younger and older cattle differed markedly in this study and statistical analysis revealed a significant difference between these two groups. Although there is variation between farms, the information obtained from the questionnaire showed that young stock are managed in a different way from adults. Most North Island dairy farmers graze young cattle off the farm and they are commonly returned to farm at 20-23 months of age in mid-late pregnancy. On this basis these animals may have acquired the infection when they returned from grazing and the different rates of abortion would be due to previous lack of exposure to the disease. Results obtained from the serological study of an infected herd (Chap. 3) show differences in the prevalence of anti-*Neospora* antibodies in weaner heifers compared to the other different age groups. However, the interpretation of these findings is uncertain since the relationship between infection (i.e. the presence of anti-*Neospora* antibodies) and abortion has not yet been established.

Although repeated abortion in cattle previously infected with *Neospora* has been induced experimentally (Barr *et al.* 1992), it is not known how often this occurs on farms under natural conditions. In our survey, 3 farms reported suffering *Neospora* abortion in the previous year and 2 of them had suffered for the last 4 seasons (1989-1992). Unfortunately, the variable ("*Neospora* in previous year") could not be confirmed as significant in the risk factor analysis. If the data obtained from these farmers is accurate it raises important questions regarding the pathogenesis of abortion in adult cattle. Dubey (1993) has postulated that repeated abortion may be due to reactivation of bradyzoites in a previously dormant cyst when the animal is under stress. Another possibility is that the animal becomes reinfected by the ingestion of contaminated feed.

The presence of a farm with a high incidence of mummified foetuses parallels previous reports which describe this phenomenon as a possible feature of *Neospora* abortion (Thilsted *et al.* 1989; Dubey 1993). Mummified foetuses are also commonly encountered in *Toxoplasma* abortion in sheep (Beverley *et al.* 1971; Hartley and Kater 1963).

The main objective of the present study was to attempt to identify risk factors that varied significantly between farms with *Neospora* abortions and the controls. Because of the small sample size, some of the variables considered in this work revealed values with a **power** factor of about 15% (where **power** is the ability of a study to detect a difference of a given size if a difference really exists (Dawson-Saunders and Trapp 1990), so the study was unable to link any risk factors with *Neospora* abortion. Retrospective calculation of the sample size required, indicated that at least 150 questionnaire replies would be necessary in each group (cases, matched, and random) in order to provide a minimum of 80% of **power**. Thus a total of 1200 questionnaires would be necessary in the first instance assuming that there was a 40% return rate. This is four times the number mailed in the current project and it is unlikely that sufficient farmers exist with this problem in New Zealand at the present time for such a survey to yield reliable results.

Despite the problems of the small sample size in the present study the results provide directions for future research. The evidence obtained from the study confirms that *Neospora* protozoa are responsible for a large proportion of the aborted foetuses in the North Island of New Zealand and the problem therefore warrants further investigation.

CHAPTER 5.
SUMMARY AND CONCLUSIONS.

Neosporosis is now a well recognised disease entity which causes economic loss to the dairy industry world wide. In New Zealand it is also responsible for a large proportion of the abortions in dairy cattle.

One of the objectives of the present study was to find out if dogs in New Zealand were infected by *N. caninum* and to determine if they could be involved in the transmission of the disease. In a retrospective study of case material (Chap. 2), it was found that *N. caninum* had caused infection in dogs in New Zealand for at least 20 years and neosporosis should therefore be considered in the differential diagnosis of encephalitis in dogs in this country. *Neospora caninum* was identified using immunohistochemical techniques; it reacted strongly with anti-*N. caninum* serum but not with the anti-*T. gondii*. Because of the close resemblance between *T. gondii* and *N. caninum*, case of neosporosis will almost certainly have been misdiagnosed previously using conventional histopathology.

Attempts to infect puppies with *Neospora* material of bovine origin (Chap. 2) were unsuccessful. The possible reasons for the lack of infectivity of the homogenate have already been discussed and since no data has been reported in the literature of similar experiments, interpretation of this result is difficult. Nevertheless, the likelihood of a link between cattle and dogs remains strong and abortion in cattle has been induced with *N. caninum* inoculation using tissue cysts (from mouse brain) and tachyzoites (from cell cultures) (Dubey et al. 1992b). However, there is still no direct evidence to incriminate dogs in the transmission of *Neospora* spp. and the protozoa causing the disease in dogs and cattle should therefore be considered as potentially different until biologic evidence is available to the contrary. The possibility that another carnivore is involved cannot be ruled out.

Interesting results were obtained with the serological studies carried out on a herd with a recent history of *Neospora* abortion. In this study the presence of anti-*Neospora* antibodies was determined using IFA techniques in four different age-groups of cattle. The results showed that approximately 29% (56/194) of the calves, young and old cows were positive to the IFA test. In the weaner heifers, however, the prevalence was significantly lower (3% : 1/32). Since this category of animals was grazed off the farm at the time when the outbreak occurred, it seems clear that they avoided exposure to infection. This finding raises interesting questions for future investigation regarding the influence of husbandry techniques on the spread of the disease in a herd and how transmission may occur.

The serological prevalence in calves, young cows and adult cows was similar to the preliminary data published by Pare *et al.* (1994), but lower than that reported from one farm in New Zealand by Thornton *et al.* (1994). This may be a true reflection of a different prevalence in the herd or it may reflect the different "cutoff" point used in the IFA test. This, and the time of infection at which the animals are sampled should be considered when making comparisons between laboratories. In spite of these considerations, the work revealed that *Neospora* antibodies were present in a high percentage of different ages which is presumably an indication of a high rate of infection. There was also showed a high proportion of non-specific IFA reaction in the different age groups studied which may be indicative of cross-reactions with other related protozoa.

Data obtained from Batchelar and Ruakura Animal Health Laboratories revealed that protozoal lesions were found in at least 14-15% of the bovine abortions submitted in 1992. This confirms previous findings by Thornton *et al.* (1991) which indicated that protozoal-type lesions were seen in the majority of foetal brains examined from cases of infectious abortion diagnosed in the North Island. There is now solid evidence that

Neospora-infection is the most commonly diagnosed cause of infectious abortion in dairy cattle in this country.

In an attempt to gain a better understanding of the epidemiology of the disease in New Zealand, a questionnaire survey of dairy farmers in the North Island was carried out. Basic information such as age/time of abortion, seasonal distribution, and category of cattle aborting was compiled (Chap. 4), but unfortunately, attempts to identify risk factors related to the farms with *Neospora* abortion were unsuccessful because of the small size of the sample used. Nevertheless some preliminary data which may help in identifying areas for future research was obtained.

The search for *Neospora*-infection in other species is just beginning and this is an area where promising results are likely in the future. At the moment the disease has been induced experimentally in laboratory animals and cats. Isolated cases of natural neosporosis have been documented in the horse (Dubey & Porterfield 1990), goats (Dubey et al. 1992a; Barr et al. 1992), and sheep (Dubey et al. 1990c). Because protozoal abortion is rare in horses (Manktelow pers. comm.), it is presumed that *Neospora* is not an important infection in this species. In goats and sheep however, the lesions are similar to toxoplasmosis and although a vast amount of work has already been done on this parasite in New Zealand, it would not be surprising if cases of neosporosis in these species have been inadvertently misdiagnosed as toxoplasmosis. In view of the importance of the sheep industry in New Zealand such a possibility would be worthwhile investigating. New Zealand, is fortunate in having good conditions for the search for a definitive host since few carnivore species exist in this country. The recent report that non-human primates are also susceptible to *Neospora* infection (Barr et al. 1994b) raises the possibility that the disease is a zoonosis and this should therefore intensify research efforts.

APPENDIX.

DAIRY CATTLE ABORTION QUESTIONNAIRE FOR FARMERS

Name:

Address:

Veterinarian:

1. Type of farm (please tick): seasonal [] town supply []
2. How many replacement heifers did you purchase last year? []
N° bought [] N° reared []

3. How many adult cows did you purchase in 1992 ? []

Which month/s

Where from (address/district)

4. The information below is to estimate % abortions in the previous four years. Please use records if available, best guess if not.

Year	N° breeding cows in herd	N° cows that aborted	Age of aborted calves if known
1992			
1991			
1990			
1989			

5. Number of abortions each month. If you can't remember put a question mark.

Year	Jan	Feb	Mar	Apr	May	Jun	Jul	Aug	Sep	Oct	Nov	Dec
1992												
1991												
1990												
1989												

6. How many aborting cows were there in each of the following age groups ?

	2-3 ys.	more than 3 ys.
1992
1991
1990
1989

7. If known please indicate the cause of abortion in each of these cases.

1992
1991
1990
1989

8. Were any of the aborting cows kept ? (please tick) Yes [] No []

If so what was their subsequent breeding history ?

	N° cows that bred normally	N° cows that aborted again
1992
1991
1990
1989

9. Were any of the cows which aborted 1992 bought in ? (please tick)

Yes [] No []

If so please give details:

Date of purchase

Where from (address/district)

10. Were any cattle grazed off the farm in another location ?

Year	N°	Age	MS*	MF*	Location (address/district)
1992					
1991					
1990					
1989					

(*) MS: Month Started; MF: Month Finished

11. Do you have dogs/cats on your farm ? (please tick) Yes [] No []
If yes, please give numbers.

Year	DOGS			CATS		
	Adults		Puppies	Adults		Kittens
	Male	Female		Male	Female	
1992						
1991						
1990						
1989						

12. Were any new dogs/cats brought onto farm as resident pets or working animals in the last 4 years?

N° of dogs [] N° of cats []

Date

Where from (address/district)

13. Have your dogs/cats shown any sign of disease in the last year?

Dogs/cats	Date	Abortion	Dead pups/kittens	Other signs

14. Have you seen any of the followed wild carnivores on/around your farm ?

(Estimate N° please) Stoats/Ferrets Feral cats

15. What other species of animal are there on the farm?

Sheep []

Goats []

Horses []

Deer []

16. Have you had any cases of abortion diagnosed as toxoplasmosis ?
(Please tick) Yes [] No []
17. Have any new animal species, such as sheep/deer/etc, been brought onto the property ?

Year	Species	N° animals	Health (*)
1992			
1991			
1990			
1989			

(*) please mention any signs of disease which have occurred.

REFERENCES.

Abbitt, B., Craig, T.M., Jones, L.P., Huey, R.L., and Eugster A.K. (1993): Protozoal abortion in a herd of cattle concurrently infected with *Hammondia pardalis*. *Journal of the American Veterinary Medical Association* **203**: 444-448.

Alley, M.R., Jones, B.R., and Johnstone, A.C. (1983): Granulomatous meningoencephalomyelitis of dogs in New Zealand. *New Zealand Veterinary Journal* **31**: 117-119.

Anderson, M.L., Blanchard, P.C., Barr, B.C., Dubey, J.P., Hoffman, R.L., and Conrad, P.A. (1991): *Neospora*-like protozoan infection as a major cause of abortion in California dairy cattle. *Journal of the American Veterinary Medical Association* **198**: 241-244.

Anderson, M.L., Blanchard, P.C., Barr, B.C., and Hoffman, R.L. (1990): A survey of cause of bovine abortion occurring in the San Joaquin Valley, California. *Journal of Veterinary Diagnostic Investigation* **2**: 238-287.

Anderson, M.L., Picanso, J., Thurmond, M., Blanchard, P., Layton, B., Palmer, Ch., Case, J., Barr, B., Dubey, J.P. and Conrad, P. (1992): Epidemiological investigations of bovine abortion in California dairy herds. Proceeding XVII World Buiatrics Congress and XXV American Association Bovine Practitioner Conference **2**: 74-78.

Banks, K.L. (1982): Host defense in the newborn animal. *Journal of the American Veterinary Medical Association* **181**: 1053-1056.

Barr, B.C. and Anderson, M.L. (1993): Infectious diseases causing bovine abortion and fetal loss. *Veterinary Clinics of North America: Food Animal Practice* **9**: 343-369.

Barr, B.C., Anderson, M.L., Blanchard, P.C., Daft, B., Kinde, H., and Conrad, P.A., (1990): Bovine fetal encephalitis and myocarditis associated with protozoal infections. *Veterinary Pathology* **27**: 354-361.

Barr, B.C., Anderson, M.L., Dubey, J.P., and Conrad, P.A. (1991): *Neospora*-like protozoal infections associated with bovine abortions. *Veterinary Pathology* **28**: 110-116.

Barr, B.C., Anderson, M.L., Woods, L.W., Dubey, J.P., and Conrad, P.A. (1992): *Neospora*-like protozoal infections associated with abortions in goats. *Journal of Veterinary Diagnostic Investigation* **4**: 365-367.

Barr, B.C., Conrad, P.A., Breitmeyer, R., Sverlow, K., Anderson, M.L., Reynolds, J., Chauvet, A.E., Dubey, J.P., and Ardans, A.A., (1993): Congenital *Neospora* infection in calves born from cows that had previously aborted *Neospora*-infected fetuses: four cases (1990-1992). *Journal of the American*

Veterinary Medical Association **202**: 113-117.

Barr, B.C., Conrad, P.A., Sverlow, K., Tarantal, A.F., and Hendrickx, A.G. (1994b): Experimental fetal and transplacental *Neospora* infection in the nonhuman primate. *Laboratory Investigations* **71**: 236-242.

Barr, C.B., Rowe, J.D., Sverlow, K.W., BonDurant, R.H., Ardans, A.A., Oliver, M.N., and Conrad, P.A. (1994a): Experimental reproduction of bovine fetal *Neospora* infection and death with a bovine *Neospora* isolate. *Journal of Veterinary Diagnostic Investigation* **6**: 207-215.

Barta, J.R., and Dubey, J.P. (1992): Characterization of anti-*Neospora caninum* hyperimmune rabbit serum by Western blot analysis and immunoelectron microscopy. *Parasitology Research* **78**: 689-694.

Beverly, J.K.A. and Watson, W.A. (1970): Prevention of experimental and of naturally occurring ovine abortion due to toxoplasmosis. *Veterinary Record* **88**: 39-41.

Beverly, J.K.A., Watson, W.A. and Spence, J.B. (1971): The pathology of the foetus in ovine abortion due to toxoplasmosis. *Veterinary Record* **88**: 174-178.

Bjerkås, I., and Dubey, J.P., (1991): Evidence that *Neospora caninum* is identical to the *Toxoplasma*-like parasite of Norwegian dogs. *Acta Veterinaria Scandinavica* **32**: 407-410.

Bjerkås, I, Mohn, S.F. and Presthus, J. (1984): Unidentified cyst-forming sporozoon causing encephalomyelitis and myositis in dogs. *Zeitschrift für Parasitenkunde* **70**: 271-274.

Bjerkås, I, and Presthus, J. (1988): Immuno-histochemical and ultrastructural characteristics of a cyst-forming sporozoon associated with encephalomyelitis and myositis in dogs. *Acta pathologica microbiologica immunologica Scandinavica* **96**: 445-454.

Bjerkås, I, and Presthus, J. (1989): The neuropathology in Toxoplasmosis-like infection caused by a newly recognized cyst-forming sporozoon in dogs. *Acta pathologica microbiologica immunologica Scandinavica* **97**: 459-468.

Böttner, A., Charleston, W.A.G., and Hopcroft, D. (1987): The prevalence and identity of *Sarcocystis* in beef cattle in New Zealand. *Veterinary Parasitology* **24**: 157-168.

Bourdoiseau, G. (1993): La neosporose des carnivores. *Recueil Médecine Vétérinaire Spécial* **169**: 473-475.

Braund, K.G., Vandavelde, M., Walker, T.L., and Redding, R.W. (1978): Granulomatous meningoencephalomyelitis in six dogs. *Journal of the American Veterinary Medical Association* **172**: 1195-1200.

Briggs, M., and Foreyt, W. (1985): Sarcocystosis in cattle. *Compendium of Continuing Education* **7**: 396-400.

Bryan, L.A., Gajadhar, A.A., Dubey, J.P., and Haines, D.M. (1994): Bovine neonatal encephalomyelitis associated with a *Neospora* sp. protozoan. *Canadian Veterinary Journal* **35**: 111-113.

Buxton, D., and Finlayson, J. (1986): Experimental infection of pregnant sheep with *Toxoplasma gondii*: pathological and immunological observations on the placenta and foetus. *Journal of Comparative Pathology* **96**: 319-333.

Charleston, W.A.G. (1994): *Toxoplasma* and other protozoan infections of economic importance in New Zealand. *New Zealand Journal of Zoology* **21**: 67-81.

Chen, W. and Alley, M.A. (1987): Lesions of toxoplasmosis in the perirenal adipose tissue of aborted kids. *New Zealand Veterinary Journal* **35**: 176.

Cochrane, S.M., and Dubey, J.P. (1993): Neosporosis in a golden retriever dog from Ontario. *Canadian Veterinary Journal* **34**: 232-233.

Cole, D.J.W (1978): Sarcocystiasis. Resistance to infection. *Wallaceville Animal Research Centre, Annual Report 1977-1978*. 5.

Cole, R.A., Lindsay, Blagburn, B.L. and Dubey, J.P. (1990): *Neospora caninum* (Protozoa: Apicomplexa): Comparison of *in vitro* development of NC-1 and NC-3 isolates in three cell lines and three primary cell cultures. Proceedings of Southeastern Society of Parasitologists, Boone, North Carolina, April 18-20. Abstract N° 34. (cited by Dubey 1992a).

Cole, R.A., Lindsay, Blagburn, B.L. and Dubey, J.P. (1991): Vertical transmission of *Neospora caninum* (Protozoa: Apicomplexa) in mice. Proceedings of Animal Disease Research Workers in Southern States, Southern Conference on Avian Diseases and Southern Conference on Animal Parasites, Auburn, Alabama, March 1991. Abstract N° 71. (cited by Dubey 1992a).

Cole, R.A., Lindsay, D.S., Dubey, J.P., and Blagburn, B.L. (1993): Detection of *Neospora caninum* in tissue sections using a murine monoclonal antibody. *Journal of Veterinary Diagnostic Investigation* **5**: 579-584.

Collins, G.H. and Charleston, W.A.G. (1979): Studies on *Sarcocystis* species IV: A species infecting dogs and goats; development in goats. *New Zealand Veterinary Journal* **27**: 260-262.

Conrad, P.A., Barr, B.C., Sverlow, K.W., Anderson, M., Daft, B., Kinde, H., Dubey, J.P., Munson, L., and Ardans, A. (1993a): *In vitro* isolation and characterization of *Neospora* sp. from aborted bovine fetus. *Parasitology* **106**: 239-249.

Conrad, P.A., Barr, B.C., Sverlow, K.W., Anderson, M.L., and

Rowe, J.D., (1992): Bovine fetal encephalitis and myocarditis associated with protozoa. *Veterinary Record* **130**: 147.

Conrad, P.A., Sverlow, K.W., Anderson, M.L., Rowe, J.D., BonDuran, R., Tuter, G., Breitmeyer, R., and Palmer, C.. (1993b): Detection of serum antibody responses in cattle with natural or experimental *Neospora* infections. *Journal of Veterinary Diagnostic Investigation* **5**: 572-578.

Cordy, D.R. (1979): Canine granulomatous meningoencephalomyelitis. *Veterinary Pathology* **16**: 325-333.

Corner, A.H., Mitchel, D., Meads, E.D. and Taylor, P.A. (1963): Dalmeny disease. An infection of cattle presumed to be caused by unidentified protozoon. *Canadian Veterinary Journal* **4**: 252-263.

Cuddon, P., Lin, D., Bowman, D.D., Lindsay, D.S., Miller, T.K., Duncan, I.D., de Lahunta, A., Cummings, J., Suter, M., Cooper, B., King, J.M., and Dubey, J.P. (1992): *Neospora caninum* infection in English Spring Spaniel littermates. *Journal of Veterinary Internal Medicine* **6**: 325-332.

Cummings, J.F., de Lahunta, A., Suter, M.M., and Jacobson, R. (1988): Canine protozoan polyradiculoneuritis. *Acta Neuropathologica* **76**: 46-54.

Dawson-Saunders, B. & Trapp, R.G. (1990): Basic and clinical biostatistics. Eds. Langan, C. Publisher: Appleton & Lange.

Dubey, J.P. (1976): A review of *Sarcocystis* of domestic animals and other coccidia of cats and dogs. *Journal of the American Veterinary Medical Association* **169**: 1061-1078.

Dubey, J.P. (1977): *Toxoplasma*, *Hammondia*, *Besnoitia*, *Sarcocystis*, and other tissue cyst-forming coccidia of man and animals. In: Kreier, J.P. ed. Parasitic protozoa, New York: Academic Press Inc. **3**: 101-237.

Dubey, J.P. (1981a): Early developmental stages of *Sarcocystis cruzi* in calf fed sporocysts from coyote feces. *Journal of Protozoology* **28**: 431-433.

Dubey, J.P. (1981b): Abortion and death in goats inoculated with *Sarcocystis* sporocysts from coyote feces. *Journal of the American Veterinary Medical Association* **178**: 700-703.

Dubey, J.P. (1982a): Repeat transplacental transfer of *Toxoplasma gondii* in dairy goats. *Journal of the American Veterinary Medical Association* **180**: 1220-1221.

Dubey, J.P. (1982b): Sarcocystosis in neonatal bison fed *Sarcocystis cruzi* sporozoites derived from cattle. *Journal of the American Veterinary Medical Association* **181**: 1272-1274.

Dubey, J.P. (1983a): Distribution of cysts and tachyzoites

in calves and pregnant cows inoculated with *Toxoplasma gondii* oocysts. *Veterinary Parasitology* **13**: 199-211.

Dubey, J.P. (1983b): Clinical sarcocystosis in calves fed *Sarcocystis hirsuta* sporocysts from cats. *Veterinary Pathology* **20**: 90-98.

Dubey, J.P. (1985): Toxoplasmosis in dogs. A review. *Canine Practice* **12**: 7-28.

Dubey, J.P., (1986): A review of toxoplasmosis in cattle. *Veterinary Parasitology* **22**: 177-202.

Dubey, J.P. (1987a): *Toxoplasma gondii* cysts in placentas of experimentally infected sheep. *American Journal of Veterinary Research* **48**: 352-353.

Dubey, J.P. (1987b): Toxoplasmosis in goats. *Agri-Practice* **8**: 43-52.

Dubey, J.P. (1989): Congenital neosporosis in a calf. *Veterinary Record* **125**: 486.

Dubey, J.P. (1990a): *Neospora caninum* : A look at a new *Toxoplasma*-like parasite of dogs and other animals. *Compendium of Continuing Education* **12**: 653-663.

Dubey, J.P. (1990b): Status of toxoplasmosis in sheep and goats in the United States. *Journal of the American Veterinary Medical Association* **196**: 259-262.

Dubey, J.P. (1990c): Status of toxoplasmosis in cattle in the United States. *Journal of the American Veterinary Medical Association* **196**: 257-258.

Dubey, J.P. (1992a): A review of *Neospora caninum* and *Neospora*-like infections in animals. *Journal of Protozoology Research* **2**. 40-52

Dubey, J.P. (1992b): Isolation of *Toxoplasma gondii* from a naturally infected beef cow. *Journal of Parasitology* **78**: 151-153.

Dubey, J.P., Acland, H.M., and Hamir, A.N. (1992a): *Neospora caninum* (Apicomplexa) in a stillborn goat. *Journal of Parasitology* **78**: 532-534.

Dubey, J.P. and Adams, A.D. (1990): Prevalence of *Toxoplasma gondii* antibodies in dairy goats from 1982 to 1984. *Journal of the American Veterinary Medical Association* **196**: 295-296.

Dubey, J. P., and Beattie, C.P. (1988): *Toxoplasmosis of Animals and Man*. CRC Press, Inc. Boca Raton, Florida.

Dubey, J.P., and Bergeron, J.A. (1982): Sarcocystosis as a cause of placentitis and abortion in cattle. *Veterinary Parasitology* **19**: 315-318.

Dubey, J.P., Carpenter, J.L., Speer, C.A., Topper, M.J., and Uggla, A. (1988a): Newly recognized fatal protozoan disease of dogs. *Journal of the American Veterinary Medical Association* **192**: 1269-1285.

Dubey, J.P., Desmonts, G., McDonald, C. and Walls, K.W. (1985): Serologic evaluation of cattle inoculated with *Toxoplasma gondii*: comparison of Sabin-Feldman dye test and other agglutination tests. *American Journal of Veterinary Research* **46**: 1085-1088.

Dubey, J.P., and Fayer, R. (1983): Sarcocystosis. *British Veterinary Journal* **139**: 371-377.

Dubey, J.P., Hartley, W.J., and Lindsay, D.S. (1990b): Congenital *Neospora caninum* infection in a calf with spinal cord anomaly. *Journal of the American Veterinary Medical Association* **197**: 1043-1044.

Dubey, J.P., Hartley, W.J., Lindsay, D.S., and Topper, M.J. (1990c): Fatal congenital *Neospora caninum* infection in a lamb. *Journal of Parasitology* **76**: 127-130.

Dubey, J.P., Hattel, A.L., Lindsay, D.S., and Topper, M.J., (1988b): Neonatal *Neospora caninum* infection in dogs : Isolation of the causative agent and experimental transmission. *Journal of the American Veterinary Medical Association* **193**: 1259-1263.

Dubey, J.P., Higgins, R.J., Smith, J.H., and O'Toole, T. (1990a): *Neospora caninum* encephalomyelitis in a British dog. *Veterinary Record* **126**: 193-194.

Dubey, J.P., Janovitz, E.B., and Skowronek, A.J., (1992c): Clinical neosporosis in a 4-week-old Hereford calf. *Veterinary Parasitology* **43**: 137-141.

Dubey, J.P., and Kirkbride, C.A. (1984): Epizootics of ovine abortion due to *Toxoplasma gondii* in north central United States. *Journal of the American Veterinary Medical Association* **184**: 657-660.

Dubey, J.P., Koestner, A., and Piper, R.C. (1990f): Repeated transplacental transmission of *Neospora caninum* in dogs. *Journal of the American Veterinary Medical Association* **197**: 857-860.

Dubey, J.P., Leathers, C.W., and Lindsay, D.S. (1989a): *Neospora caninum*-like protozoon associated with fatal myelitis in newborn calves. *Journal of Parasitology* **75**: 146-148.

Dubey, J.P., Leek, R.G., and Fayer, R. (1986c): Prevalence, transmission, and pathogenicity of **Sarcocystis gigantea** of sheep. *Journal of the American Veterinary Medical Association* **188**: 151-154.

Dubey, J.P., and Lindsay, D.S., (1989a): Transplacental *Neospora caninum* infection in cats. *Journal of Parasitology* **75**:

765-771.

Dubey, J.P., and Lindsay, D.S., (1989b): Fatal *Neospora caninum* infection in kittens. *Journal of Parasitology* **75**: 148-151.

Dubey, J.P., and Lindsay, D.S. (1989c): Transplacental *Neospora caninum* infection in dogs. *American Journal of Veterinary Research* **50**: 1578-1579.

Dubey, J.P., and Lindsay, D.S. (1990a): *Neospora caninum* induced abortion in sheep. *Journal of Veterinary Diagnostic Investigations* **2**: 230-233.

Dubey, J.P., and Lindsay, D.S. (1990b): Neosporosis in dogs. *Veterinary Parasitology* **36**: 147-151.

Dubey, J.P., and Lindsay, D.S. (1993): Neosporosis. *Parasitology Today* **9**: 452-458.

Dubey, J.P., Lindsay, D.S., Anderson, M.L., Davies, S.W., and Shen, K.S. (1992b): Induced transplacental transmission of *Neospora caninum* in cattle. *Journal of the American Veterinary Medical Association* **201**: 709-713.

Dubey, J.P., Lindsay, D.S., and Lipscomb, T.P. (1990d): Neosporosis in cats. *Veterinary Pathology* **27**: 335-339.

Dubey, J.P., Miller, S., Desmonts, G., Thulliez, P., and Anderson, W.R., (1986b): *Toxoplasma gondii*-induced abortion in goats. *Journal of the American Veterinary Medical Association* **188**: 159-162.

Dubey, J.P., Miller, S., Lindsay, D.S., and Topper, M.J. (1990e): *Neospora caninum* associated myocarditis and encephalitis in an aborted calf. *Journal of Veterinary Diagnostic Investigation* **2**: 66-69.

Dubey, J.P., Miller, S., Powell, E.C., and Anderson, W.R., (1986a): Epizootiologic investigations on sheep farms with *Toxoplasma gondii*- induced abortions. *Journal of the American Veterinary Medical Association* **188**: 155-158.

Dubey, J.P., and Porterfield, M.L. (1990): *Neospora caninum* (Apicomplexa) in an aborted equine fetus. *Journal of Parasitology* **76**: 732-734.

Dubey, J.P. and Sharma, S.P. (1980): Parasitemia and tissue infection in sheep fed with *Toxoplasma gondii* oocysts. *Journal of Parasitology* **66**: 111-114.

Dubey, J.P., Speer, C.A., Callis, G., and Blixt, J.A. (1982): Development of the sheep - canid cycle of *Sarcocystis tenella*. *Canadian Journal of Zoology* **60**: 2464-2477.

Dubey, J.P., Speer, C.A. and Douglas, G. (1980): Development

and ultrastructure of first-generation meronts of *Sarcocystis cruzi* in calves fed sporocysts from coyote feces. *Journal of Protozoology* **27**: 380-387.

Dubey, J.P., Speer, C.A. and Epling, G.P. (1982): Sarcocystosis in newborn calves fed *Sarcocystis cruzi* sporocysts from coyotes. *American Journal of Veterinary Research* **43**: 2147-2164.

Dubey, J.P., Speer, C.A., Epling, G.P., and Blixt, J.A. (1984): *Sarcocystis capranis*: Development in goats, dogs and coyotes. *International Goat and Sheep Research* **3**: 252-265.

Dubey, J.P., Speer, C.A., and Fayer, R. (1989b): Sarcocystosis of Animals and Man. CRC Press, Inc. Boca Raton, Florida.

Dubey, J.P., and Towle, A. (1986): Toxoplasmosis in sheep: a review and annotated bibliography. London: miscellaneous publication N° 10 of the Commonwealth Institute of Parasitology 1-152.

Dubey, J.P., Weisbrode, S.E., Speer, C.A. and Sharma, S.P. (1981): Sarcocystosis in goats: clinical signs and pathologic and hematologic findings. *Journal of the American Veterinary Medical Association* **178**: 683-699.

Dubey, J.P., and Welcome, F.L. (1988): *Toxoplasma gondii*-induced abortion in sheep. *Journal of the American Veterinary Medical Association* **193**: 679-700.

Elder, J.K., Pepper, P.M., Hill, M.W.M., and Ward, W.H. (1985): The significance of leptospiral titres associated with bovine abortion. *Australian Veterinary Journal* **62**: 258-262.

Ellis, J., Luton, K., Baverstock, P.R., Brindley, P.J., Nimmo, K.A., and Johnson, A.M. (1994): The phylogeny of *Neospora caninum*. *Molecular and Biochemical Parasitology* **64**: 303-311.

Fayer, R. (1980): Epidemiology of protozoan infections: the coccidia. *Veterinary Parasitology* **6**: 75-103.

Fayer, R., and Dubey, J.P. (1986): Bovine sarcocystosis. *Compendium of Continuing Education* **8**: 131-141.

Fayer, R., Dubey, J.P. and Leek, R.G. (1982): Infectivity of *Sarcocystis* spp. from bison, elk, moose, and cattle for cattle via sporocysts from coyotes. *Journal of Parasitology* **68**: 681-685.

Fayer, R., Johnson, J. and Lunde, M. (1976): Abortion and other signs of disease in cows experimentally infected with *Sarcocystis fusiformis* from dogs. *The Journal of Infectious Diseases* **134**: 624-628.

Fayer, R., Lynch, P.G., Leek, R.G. and Gasbarre, L.C. (1983): Effects of sarcocystosis on milk production of dairy cows.

Journal of the American Veterinary Association **66**: 904-908.

Frelier, F., Mayhew, I.G., Fayer, R., and Lunde, M.N. (1977): Sarcocystosis: A clinical outbreak in dairy calves. *Science* **195**: 1341-1342.

Frelier, F., Mayhew, I.G., and Pollock, R. (1979): Bovine Sarcocystosis: pathologic features of naturally occurring infection with *Sarcocystis cruzi*. *American Journal of Veterinary Research* **40**: 651-657.

Frenkel, J.K. (1990): Transmission of toxoplasmosis and the role of immunity in limiting transmission and illness. *Journal of the American Veterinary Medical Association* **196**: 233-240.

Fritz, D. (1992): Protozoose cutanéé à *Neospora caninum* chez un chien. Proceedings Congrès C.N.V.S.P.A., Paris, 20 novembre. 310.

Giles, R.C., Tramontin, R., Kadel, W.l., Whitaker, K., Miksch, D., Bryant, D.W., and Fayer, R. (1980): Sarcocystosis in cattle in Kentucky. *Journal of the American Veterinary Medical Association* **176**: 543-548.

Hartley, W.J., Jebson, J.L. and McFarlane, D. (1954): New Zealand type 2 abortion in ewes. *Australian Veterinary Journal* **30**: 216-218.

Hartley, W.J. and Bridge, P.S. (1975): A case of suspected congenital *Toxoplasma* encephalomyelitis in a lamb associated with a spinal cord anomaly. *British Veterinary Journal* **131**: 380-384.

Hartley, W.J. and Kater, J.C. (1963): The pathology of *Toxoplasma* infection in the pregnant ewe. *Research in Veterinary Science* **4**: 326-332.

Hay, W.H., Shell, L.G., Lindsay, D.S., and Dubey, J.P. (1990): Diagnosis and treatment of *Neospora caninum* infection in a dog. *Journal of the American Veterinary Medical Association* **197**: 87-89.

Hilali, M., Lindeberg, R., Walter, T. and Wallin, B. (1986): Enigmatic cyst-forming sporozoon in the spinal cord of a dog. *Acta Veterinaria Scandinavia* **27**: 623-625.

Holmdahl, O.J., Mattsson, J.G., Uggla, A. and Johansson, K.E. (1994): The phylogeny of *Neospora caninum* and *Toxoplasma gondii* based on ribosomal RNA sequences. *FEMS Microbiology Letters* **119**: 187-192.

Hong, C.B., Giles, R.C., Newman, L.E. and Fayer, R. (1982): Sarcocystosis in an aborted bovine fetus. *Journal of the American Veterinary Medical Association* **181**: 585-588.

Hubbert, W.T., Booth, G.D., Bolton, W.D., Dunne, H.W. McEntee, K., Smith, R.E., and Tourtellotte, M.E. (1973): Bovine

abortion in five Northeastern states, 1960-1970: evaluation of diagnostic laboratory data. *Cornell Veterinarian* **63**: 291-316.

Jacobson, L.S. and Jardine, J.E. (1993): *Neospora caninum* infection in three labrador littermates. *Journal of South Africa Veterinary Association* **64**: 47-51.

Jardine, J.E. and Dubey, J.P. (1992): Canine neosporosis in South Africa. *Veterinary Parasitology* **44**: 291-294.

Jardine, J.E. and Last, R.D. (1993): *Neospora caninum* in aborted twin calves. *Journal of South Africa Veterinary Association* **64**: 101-102.

Jeffrey, M. (1993): Sarcocystosis of sheep. *In Practice* **5**: 2-8.

Johnson, A.J., Hildebrant, P.K and Fayer, R.F. (1975): Experimentally induced *Sarcocystis* infection in calves: pathology. *American Journal of Veterinary Research* **36**: 995-999.

Kirkbride, C.A. (1985a): Managing an outbreak of livestock abortion - 2: diagnosis and control of bovine abortion. *Veterinary Medicine* **80**: 70-79.

Kirkbride, C.A. (1985b): Managing an outbreak of livestock abortion - 4: diagnosis and control of ovine abortion. *Food animal practice*. July p: 91 - 95.

Kirkbride, C.A., Bicknell, E.J., Reed, D.E., Robl, N.G., Knudtson, W.V. and Wohlgemuth, K. (1973): A diagnostic survey of bovine abortion and stillbirth in the Northern Plains States. *Journal of the American Veterinary Medical Association* **162**: 556-560.

Leek, R.G. and Fayer, R. (1977): Sheep experimentally infected with *Sarcocystis* from dogs. *Cornell Veterinarian* **68**:108-123.

Levine, N.D. (1988): The protozoan phylum Apicomplexa. C.R.C. Press, Boca Raton, Florida.

Levine, N.D., Corliss, J.O., Cox, F.E.G., Deroux, G., Grain, J., Honigberg, B.M., Leedale, G.F., Loeblich, A.R., Lom, J., Lynn, D., Merinfeld, E.G., Page, F.C., Poljansky, G., Sprague, G., Vavra, J. and Wallace, F.J. (1980): A newly revised classification of the protozoa. *Journal of Parasitology* **27**: 37-58.

Lindsay, D.S., Blagburn, B.L. and Dubey, J.P. (1990): Infection of mice with *Neospora caninum* (Protozoa: Apicomplexa) does not protect against challenge with *Toxoplasma gondii*. *Infection and Immunity* **58**: 2699-2700.

Lindsay, D.S., Blagburn, B.L. and Dubey, J.P. (1992): Factors affecting the survival of *Neospora caninum* bradyzoites

in murine tissues. *Journal of Parasitology* **78**: 70-72.

Lindsay, D.S. and Dubey, J.P. (1989a): Immunohistochemical diagnosis of *Neospora caninum* in tissue sections. *American Journal of Veterinary Research* **50**: 1981-1983.

Lindsay, D.S. and Dubey, J.P. (1989b): *In vitro* development of *Neospora caninum* (Protozoa: Apicomplexa) from dogs. *Journal of Parasitology* **75**: 163-165.

Lindsay, D.S. and Dubey, J.P. (1989c): *Neospora caninum* (Protozoa: Apicomplexa) infection in rats. *Canadian Journal of Zoology* **68**: 1595-1599.

Lindsay, D.S. and Dubey, J.P. (1989d): *Neospora caninum* (Protozoa: Apicomplexa) infection in mice. *Journal of Parasitology* **75**: 772-779.

Lindsay, D.S. and Dubey, J.P. (1990a): Effects of sulfadiazine and amprolium on *Neospora caninum* (Protozoa: Apicomplexa) infection in mice. *Journal of Parasitology* **76**: 177-179.

Lindsay, D.S. and Dubey, J.P. (1990b): Infection in mice with tachyzoites and bradyzoites of *Neospora caninum* (Protozoa: Apicomplexa): *Journal of Parasitology* **76**: 410-413.

Lindsay, D.S., Speer, C.A., Toivio-Kinnucan, M.A., Dubey, J.P. and Blagburn, B.L. (1993a): Use of infected cultured cells to compare ultrastructural features of *Neospora caninum* from dogs and *Toxoplasma gondii*. *American Journal of Veterinary Research* **54**: 103-106.

Lindsay, D.S., Dubey, J.P., Cole, R.A., Nuehring, L.P. and Blagburn, B.L. (1993b): *Neospora*-induced protozoal abortions in cattle. *Compendium of Continuing Education* **15**: 882-889.

Manwell, R.D. (1977): Gregarines and Haemogregarines. In: Kreier, J.P. ed. *Parasitic protozoa*, New York: Academic Press Inc. **3**: 1-32.

Mayhew, I.G., Smith, K.C., Dubey, J.P., Gatward, L.K. and McGlennon, N.J. (1991): Treatment of encephalomyelitis due to *Neospora caninum* in a litter of puppies. *Journal of Small Animal Practice* **32**: 609-612.

Mitchell, M.A. (1988): The prevalence of macroscopic sarcocysts in New Zealand cattle at slaughter. *New Zealand Veterinary Journal* **36**: 35-38.

McCausland, I.P., Badman, R.T., Hides, S. and Slee, K.J. (1984): Multiple apparent *Sarcocystis* abortion in four bovine herds. *Cornell Veterinarian* **74**: 146-154.

McIntosh, D.W. and Haines, D.M. (1994): *Neospora* infection in an aborted fetus in British Columbia. *Canadian Veterinary*

Journal **35**: 114-115.

McKenna, P.B. (1978): *Coccidia* (Protozoa: Sporozoasida) of cats and dogs. Ms Phil Thesis, Massey University.

McNamee, P. and Jeffrey, M. (1994): *Neospora*-associated bovine abortion in Northern Ireland. *Veterinary Record* **133**: 48.

Mehdi, N.A.Q., Kazacos, K.K. and Carlton, W.W. (1983): Fatal disseminated toxoplasmosis in a goat. *Journal of the American Veterinary Medicine Association* **183**: 115-117.

Mehlhorn, H. and Frenkel, J.K., (1980): Ultrastructural comparison of cysts and zoites of *Toxoplasma gondii*, *Sarcocystis muris*, and *Hammondia hammondi* in skeletal muscle of mice. *Journal of Parasitology* **66**: 59-67.

Munday, B.L. (1972): Serological evidence of *Toxoplasma* infection in isolated groups of sheep. *Research in Veterinary Science* **13**: 100-102.

Munday, B.L. (1978): Bovine toxoplasmosis : experimental infection. *International Journal of Parasitology* **8**: 285-288.

Munday, B.L. (1981): Premature parturition in ewes inoculated with *Sarcocystis canis*. *Veterinary Parasitology* **9**: 17-26.

Munday, B.L., Dubey, J.P., and Mason, R.W. (1990): *Neospora caninum* infection in dogs. *Australian Veterinary Journal* **67**: 76-77.

Munday, B.L. and Mason, R.W. (1979): Toxoplasmosis as a cause of perinatal death in goats. *Australian Veterinary Journal* **55**: 485-487.

Munday, B.L., Mason, R.W., and Cumming, R. (1973): Observations on disease of the central nervous system of cattle in Tasmania. *Australian Veterinary Journal* **49**: 451-455.

Nichols, B.A. and Chiappino, M.L. (1987): Cytoskeleton of *Toxoplasma gondii*. *Journal of Protozoology* **34**: 217-226.

Nietfeld, J.C., Dubey, J.P., Anderson, L.M., Libal, M.C., Yaeger, M.J., and Regg, D.N. (1992): *Neospora*-like protozoan infection as a cause of abortion in dairy cattle. *Journal of Veterinary Diagnostic Investigation* **4**: 223-226.

Nurse, G.H. and Lenghaus, C. (1986): An outbreak of *Toxoplasma gondii* abortion, mummification and perinatal death in goats. *Australian Veterinary Journal* **63**: 27-29.

Obendorf, D.L and Mason, R. (1990): *Neospora caninum* infection detected in a bovine aborted foetus. *Australian Society of Veterinary Pathology Report* **28**: 36-37.

Obendorf, D.L., Statham, P., and Munday, B.L. (1990): Resistance to *Toxoplasma* abortion in female goats previously exposed to *Toxoplasma* infection. *Australian Veterinary Journal* **67**: 233-234.

Olds, D., Cooper, T., and Thrift, F.A. (1979): Effect of days open on economic aspects of current lactation. *Journal of the American Veterinary Medical Association* **62**: 1167-1170.

Ogino, H., Watanabe, E., Watanabe, S., Agawa, H., Narita, M., Haritani, M., and Kawashima, K. (1992): Neosporosis in the aborted fetus and newborn calf. *Journal of Comparative Pathology* **107**: 231-237.

Opel, U., Charleston, W.A.G., Pomroy, W.E. and Rommel, M. (1991): A survey of the prevalence of *Toxoplasma* infection in goats in New Zealand and a comparison of the latex agglutination and indirect fluorescence tests. *Veterinary Parasitology* **40**: 181-186.

Osburn, B.I., MacLachlan, N.J., and Terrell, T.G. (1982): Ontogeny of the Immune system. *Journal of the American Veterinary Medical Association* **181**: 1049-1052.

O'Toole, D. (1987): Experimental ovine Sarcocystosis: sequential ultrastructural pathology in skeletal muscle. *Journal of Comparative Pathology* **97**: 51-60.

O'Toole, D., and Jeffrey, M. (1987): Congenital sporozoan encephalomyelitis in a calf. *Veterinary Record* **121**: 563-566.

Otter, A., Griffiths, I.B., and Jeffrey, M. (1993): Bovine *Neospora caninum* abortion in the UK. *Veterinary Record* **133**: 375.

Pare, J., Thurmond, M.C., and Hietala, S.K. (1994): Congenital *Neospora* infection in dairy cattle. *Veterinary Record* **134**: 531-532.

Parish, S.M., Maag-Miller, L., Besser, T.E., Weidner, J.P., McElwain, T., Knowles, D.P., and Leathers, C.W. (1987): Myelitis associated with protozoal infection in newborn calves. *Journal of the American Veterinary Medical Association* **191**: 1599-1600.

Poncelet, L., Bjerksås, I., Charlier, G., Coignoul, F., Losson, B. and Balligand, M. (1990): Confirmation de la présence de *Neospora caninum* en Belgique. *Annales de Médecine Vétérinaire* **134**: 501-503.

Reiten, A.C., Jense, R. and Griner, L.A. (1966): Eosinophilic myositis (sarcosporidiosis; sarco) in beef cattle. *American Journal of Veterinary Research* **27**: 903-

Rhyan, J.C., and Dubey, J.P., (1984): Ovine abortion and neonatal death due to toxoplasmosis in Montana. *Journal of the American Veterinary Medical Association* **184**: 661-664.

Rogers, D.G., Grotelueschen, D.M., Anderson, M.L., McCullough, M.S., Shain, W.S., and Dubey, J.P., (1993): Endemic protozoal abortion in dairy cow herd. *Agri-practice* **14**: 16-21.

Ruff, M.D. and Reid, W.M. (1977): Avian coccidia. In: Kreier, J.P. ed. *Parasitic Protozoa*, New York: Academic Press Inc. **3**: 33-69.

Sanger, V.L., Chamerlain, D.M., Chamerlain, K.W., Cole, C.R. and Farrell, R.L. (1953): Toxoplasmosis. V. Isolation of *Toxoplasma* from cattle. *Journal of the American Veterinary Medical Association* **123**: 87-91.

Sheahan, B.J., Caffrey, J.F., Dubey, J.P., and McHenry, D.F., (1993): *Neospora caninum* encephalomyelitis in seven dogs. *Irish Veterinary Journal* **46**: 3-7.

Sheffield, H.G. (1968): Observations on the fine structure of the "cyst stage" of *Besnoitia jellisoni*. *Journal of Protozoology* **15**: 685-693.

Sheffield, H.G., and Melton, M.L. (1968): The fine structure and reproduction of *Toxoplasma gondii*. *Journal of Parasitology* **54**: 209-226.

Shivaprasad, H.L., Ely, R., and Dubey, J.P., (1989): A *Neospora*-like protozoan found in an aborted bovine placenta. *Veterinary Parasitology* **34**: 145-148.

Smith, C. (1993): *Neospora* threatens livestock, dogs. *Journal of the American Veterinary Medical Association* **202**: 15-20.

Smith, T.S. and Herbert, I.V. (1986): Experimental microcystis infection in lamb: serologic and immunohistochemistry. *Veterinary Record* **119**: 547-550.

Speer, C.A., and Dubey, J.P., (1989): Ultrastructure of tachyzoites, bradyzoites and tissue cysts of *Neospora caninum*. *Journal of Protozoology* **36**: 458-463.

Stalheim, O. H. V., Hubbert, W. T., Boothe, A. D., Zimmerman, W.J., Hughes, D.E., Barnett, D, Riley, J.L. and Foley, J. (1980): Experimental toxoplasmosis in calves and pregnant cows. *American Journal of Veterinary Research* **41**: 10-13.

Thilsted, J.P., and Dubey, J.P., (1989): Neosporosis-like abortions in a herd of dairy cattle. *Journal of Veterinary Diagnostic Investigation* **1**: 205-209.

Thornton, R.N. (1987): Protozoal abortion in cattle. *Surveillance (MAF)* **14**: 15-16.

Thornton, R.N., Gajadhar, A., and Evans, J. (1994): *Neospora* abortion epidemic in a dairy herd. *New Zealand Veterinary Journal* **40**: 190-191.

Thornton, R.N., Thompson, E.J., and Dubey, J.P. (1991): *Neospora* abortion in New Zealand cattle. *New Zealand Veterinary Journal* **39**: 129-133.

Thurmond, M.C. and Picanso, J.P. (1990): A surveillance system for bovine abortion. *Preventive Veterinary Medicine* **8**: 41-53.

Thurmond, M.C., Picanso, J.P., and Hietala, S.K. (1990): Prospective serology and analysis in diagnosis of dairy cow abortion. *Journal of Veterinary Diagnostic Investigation* **2**: 274-282.

Todd, K.S. and Ernst, J.V. (1977): *Coccidia* of mammals except man. In: Kreier, J.P. ed. *Parasitic Protozoa*, New York: Academic Press Inc. **3**: 71-99.

Trees, A.J., Guy, F., Tennant, B.J., Balfour, A.H., and Dubey, J.P. (1993): Prevalence of antibodies to *Neospora caninum* in a population of urban dogs in England. *Veterinary Record* **132**: 125-126.

Trees, A.J., Guy, F., Low, J.C., Roberts, D., Buxton, D. and Dubey, J.P. (1994): Serological evidence implicating *Neospora* species as a cause of abortion in British cattle. *Veterinary Record* **134**: 405-407.

Trees, A.J., Tennant, B.J., and Kelly, D.F. (1991): Paresis in dogs and *Neospora caninum*. *Veterinary Record* **129**: 456.

Uggla, A., Dubey, J.P., Lundmark, G., and Olson, P. (1989): Encephalomyelitis and myositis in a Boxer puppy due to a *Neospora*-like infection. *Veterinary Parasitology* **32**: 255-260.

Uggla, A., Sjöland, L., and Dubey, J.P., (1987): Immunohistochemical diagnosis of toxoplasmosis in fetuses and fetal membranes of sheep. *American Journal of Veterinary Research* **48**: 348-351.

Underwood, W.J., and Rook, J.S. (1992): Toxoplasmosis infection in sheep. *Compendium of Continuing Education* **14**: 1543-1549.

Vickers, M.C., and Brooks, H.V. (1983): Suspected sarcocystis infection in an aborted bovine foetus. *New Zealand Veterinary Journal* **31**: 166.

Watson, M.E. (1916): Studies on gregarines. Ill. Biological Monographs **2**: 1-258.

Wouda, W., Visser, I.J., and Van Knapen, F. (1992): Bovine protozoal abortion. *Veterinary Record* **130**: 279.